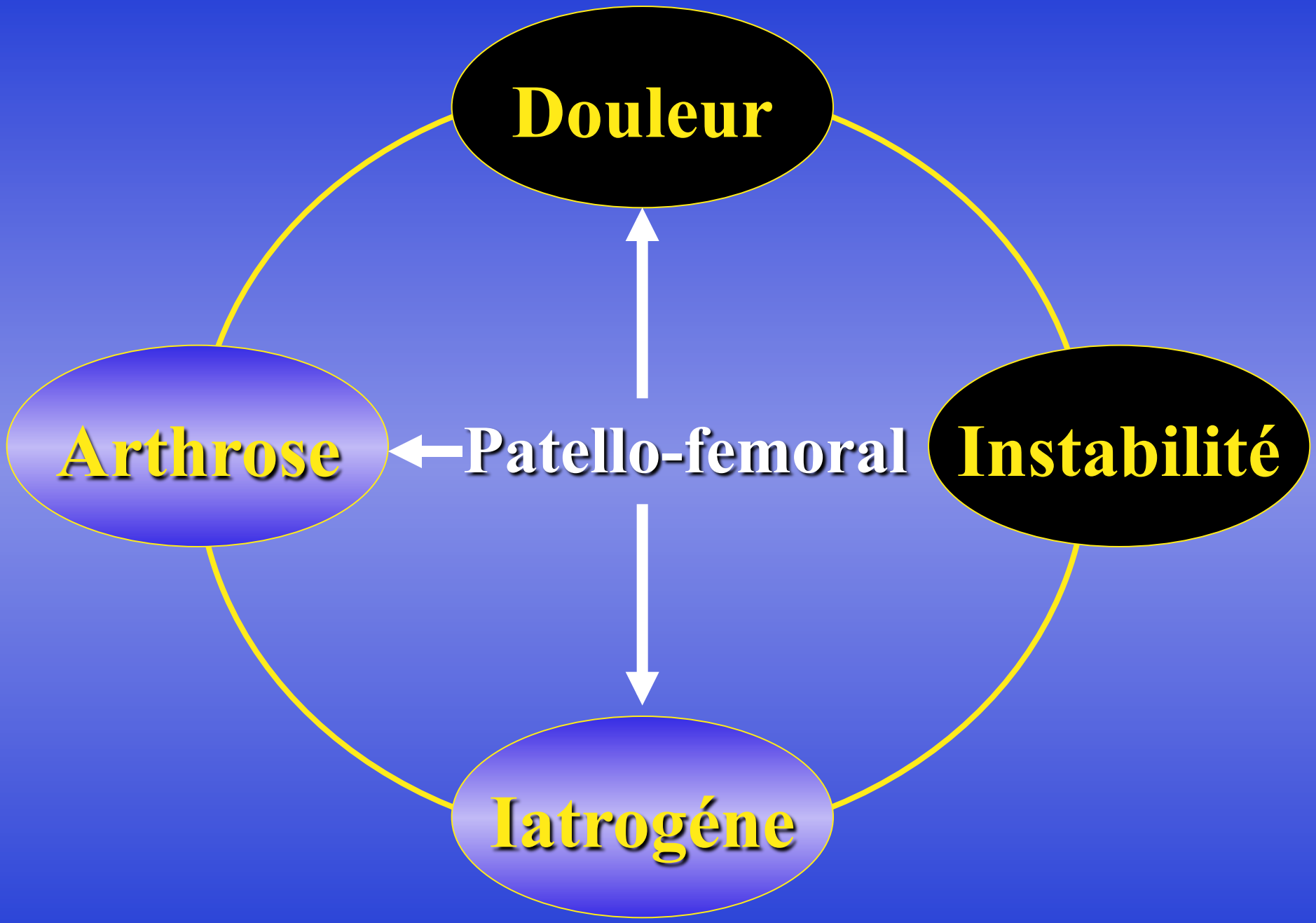
Douleur
Arthrose
Patello-femoral
Instabilité
Iatrogéne

La Rotule

Os Sésamoïde

Muscle Bi-articulaire

Anatomie Patello-Femorale?
Local system

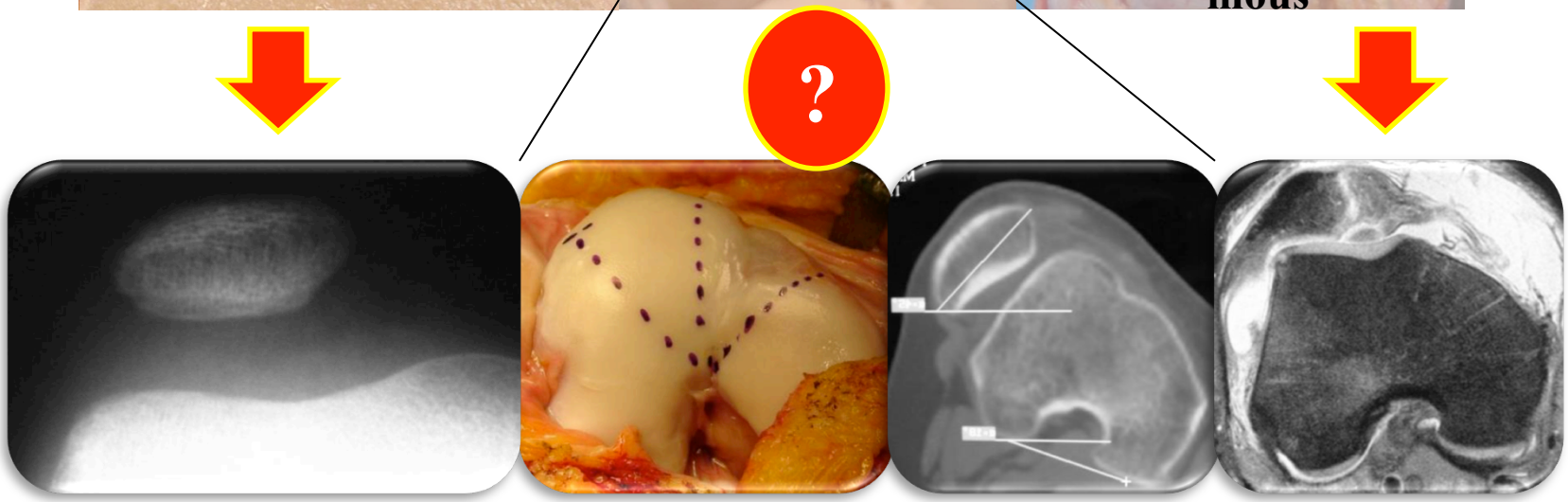

Tissus mous

Medial

Lateral

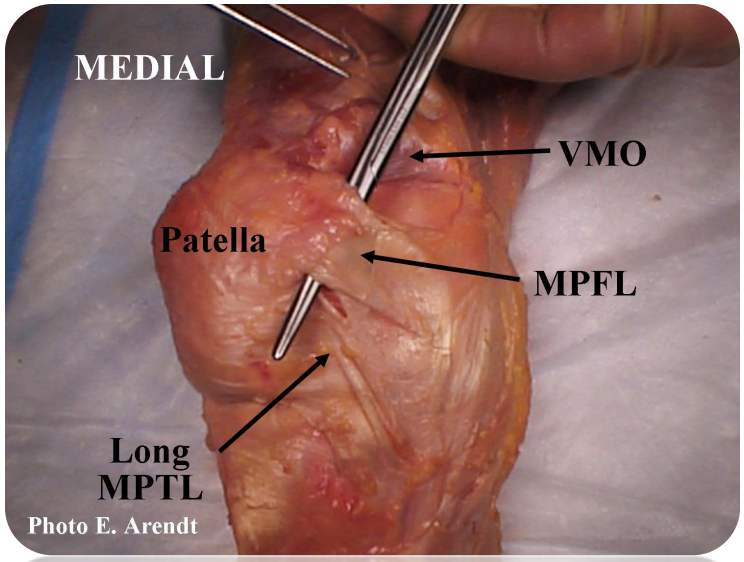

E Arendt

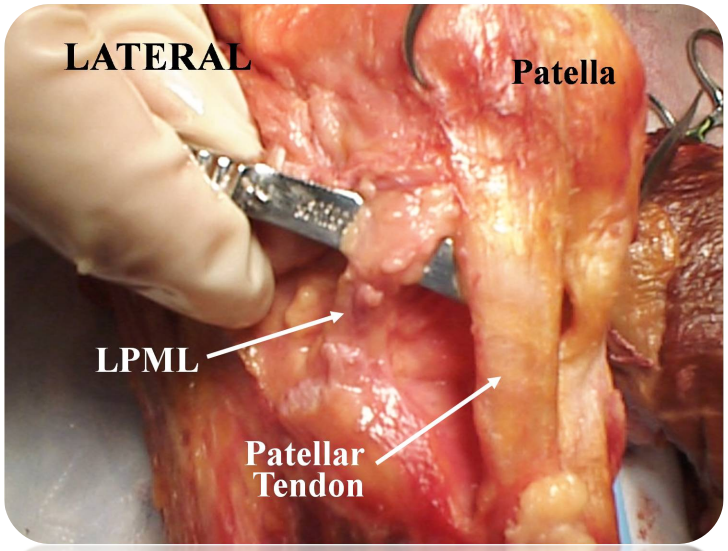

Biomechanical studies from A. Amis

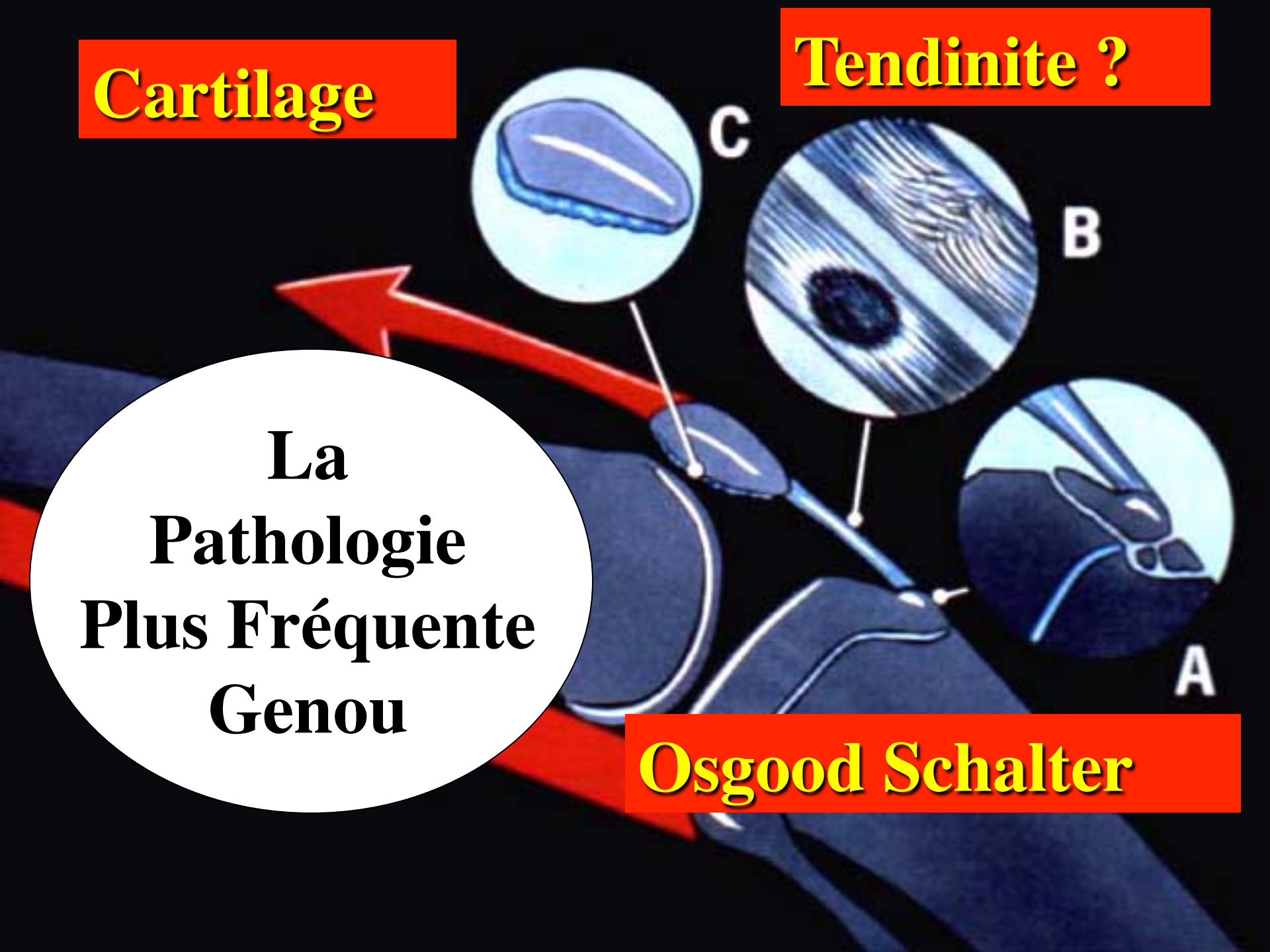
Cartilage
Tendinite ?
C
B
A
La
Pathologie
Plus Fréquente
Genou
Osgood Schalter

Comment donner une définition objective

Pathologie fémoro patellaire

David DEJOUR
COROLYON -

Les deux faces de la rotule

Instabilité

Douleur

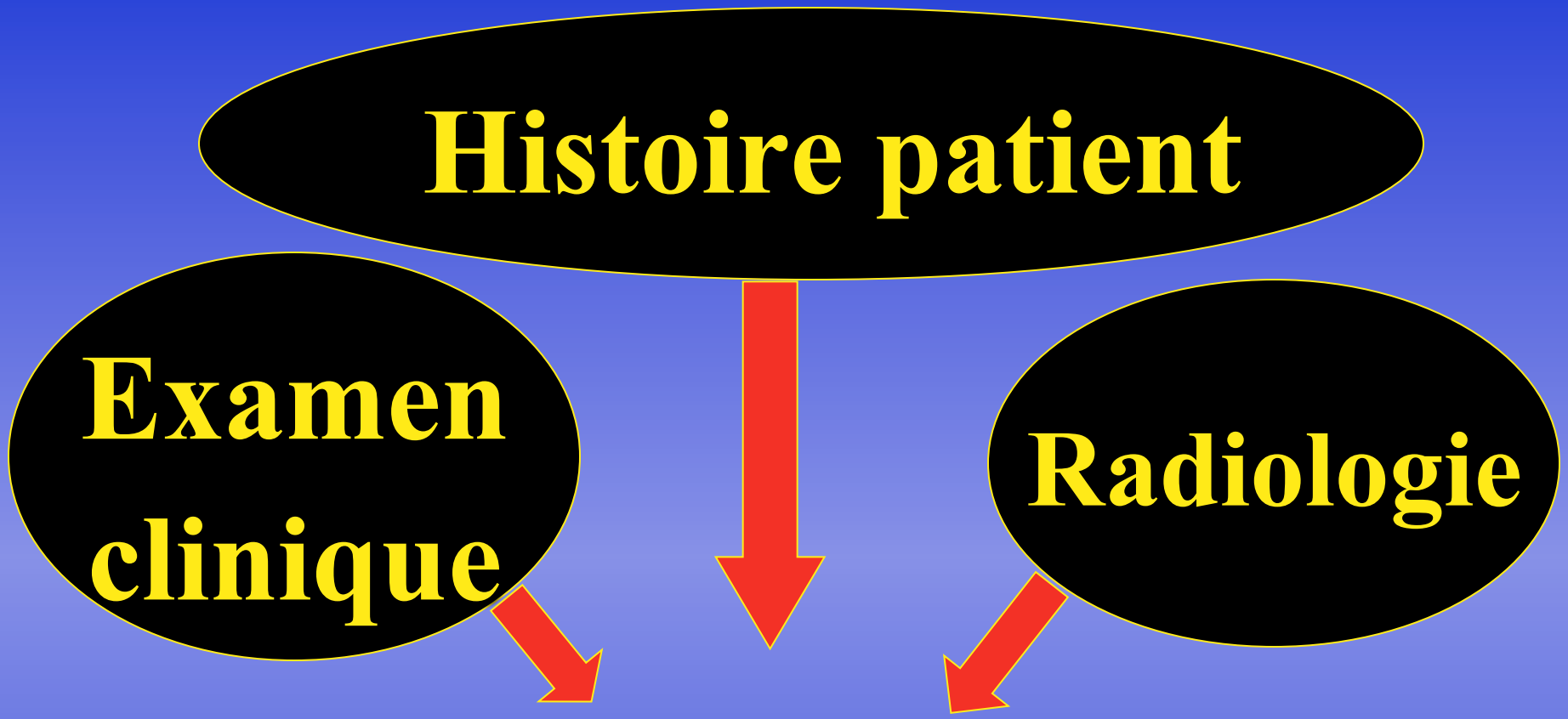

Classification

Traitement

Investigations

Première consultation

Radio Standard

Sont suffisante +++

Vérifier :

- **Dysplasie de trochlée**
- **Hauteur de rotule**

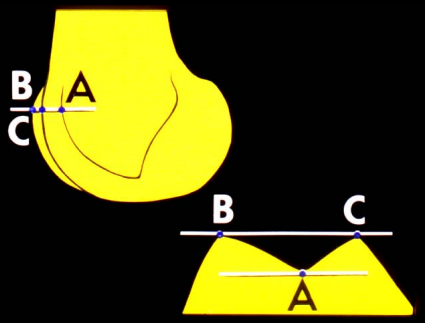

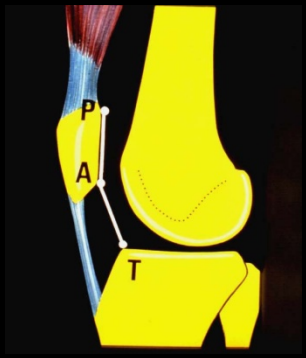

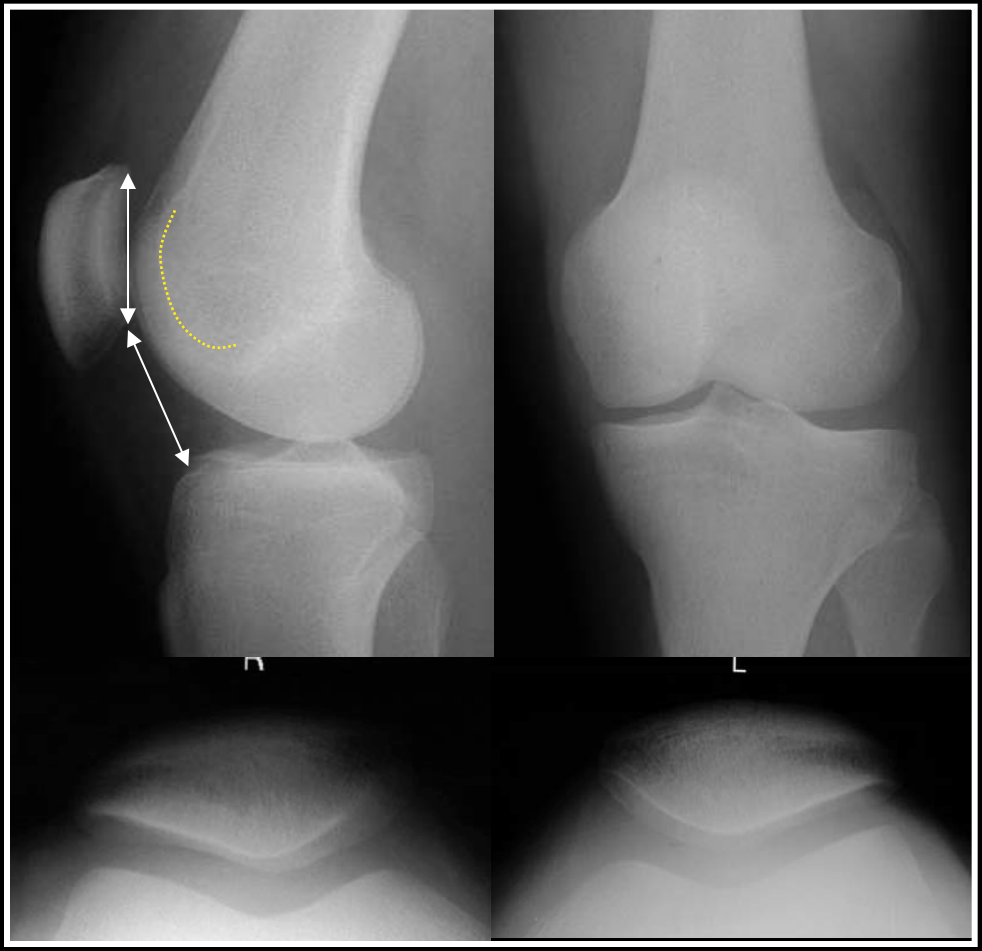

Anomalies anatomiques
&
Valeur clinique

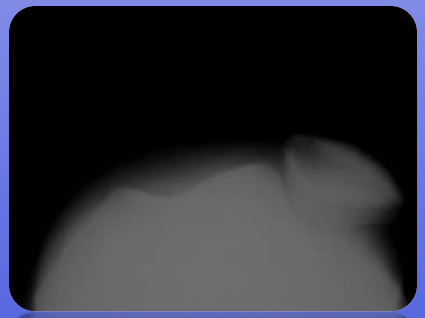

Analyse clinique1987

Témoin (n= 190) / Luxation(n= 147)

Statistical differences 4 factors (H. Dejour – G. Walch)

Dysplasie de trochlée

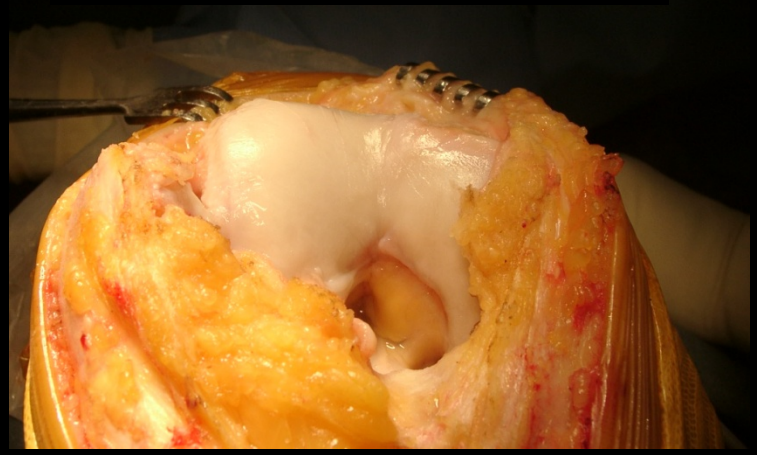

TA- TG > 20 mm

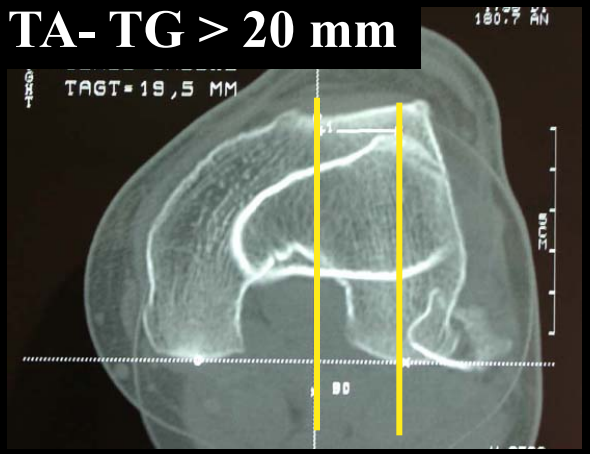

Bascule > 20°

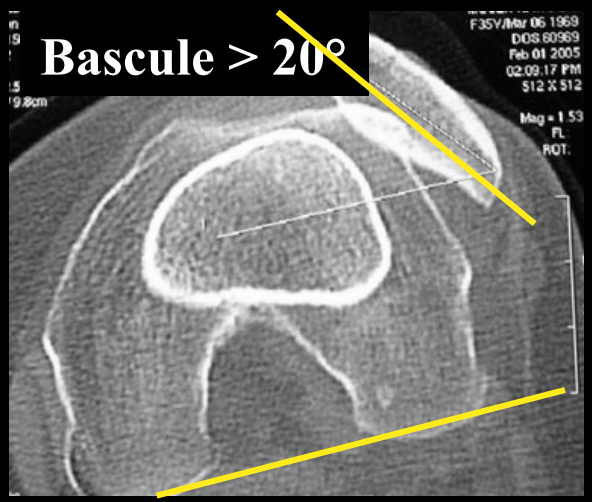

Patella Alta > 1.2

French J. Orthop. 1990
Knee Surg. Trauma 1994

DysplasieTrochlée

96 % Dislocation population

Control
3 % P = 0,001

Signe du croisement
(H. Dejour)

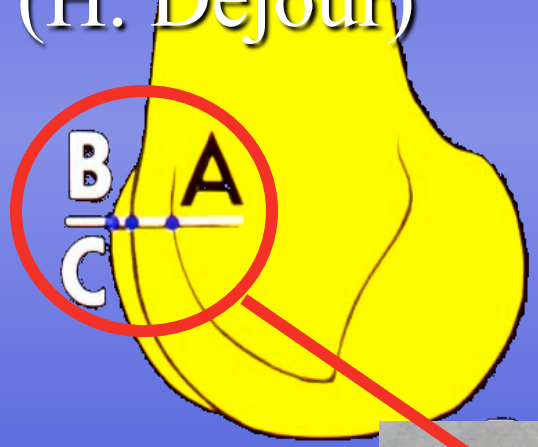



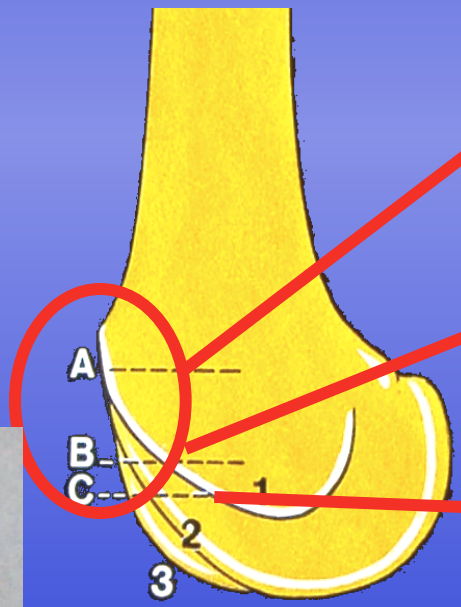

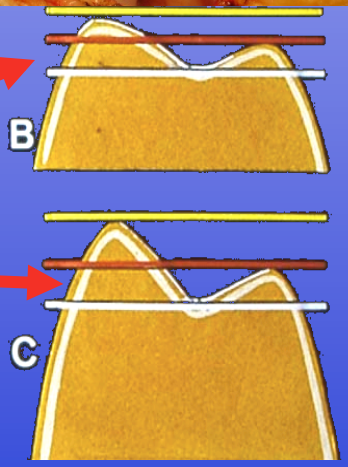

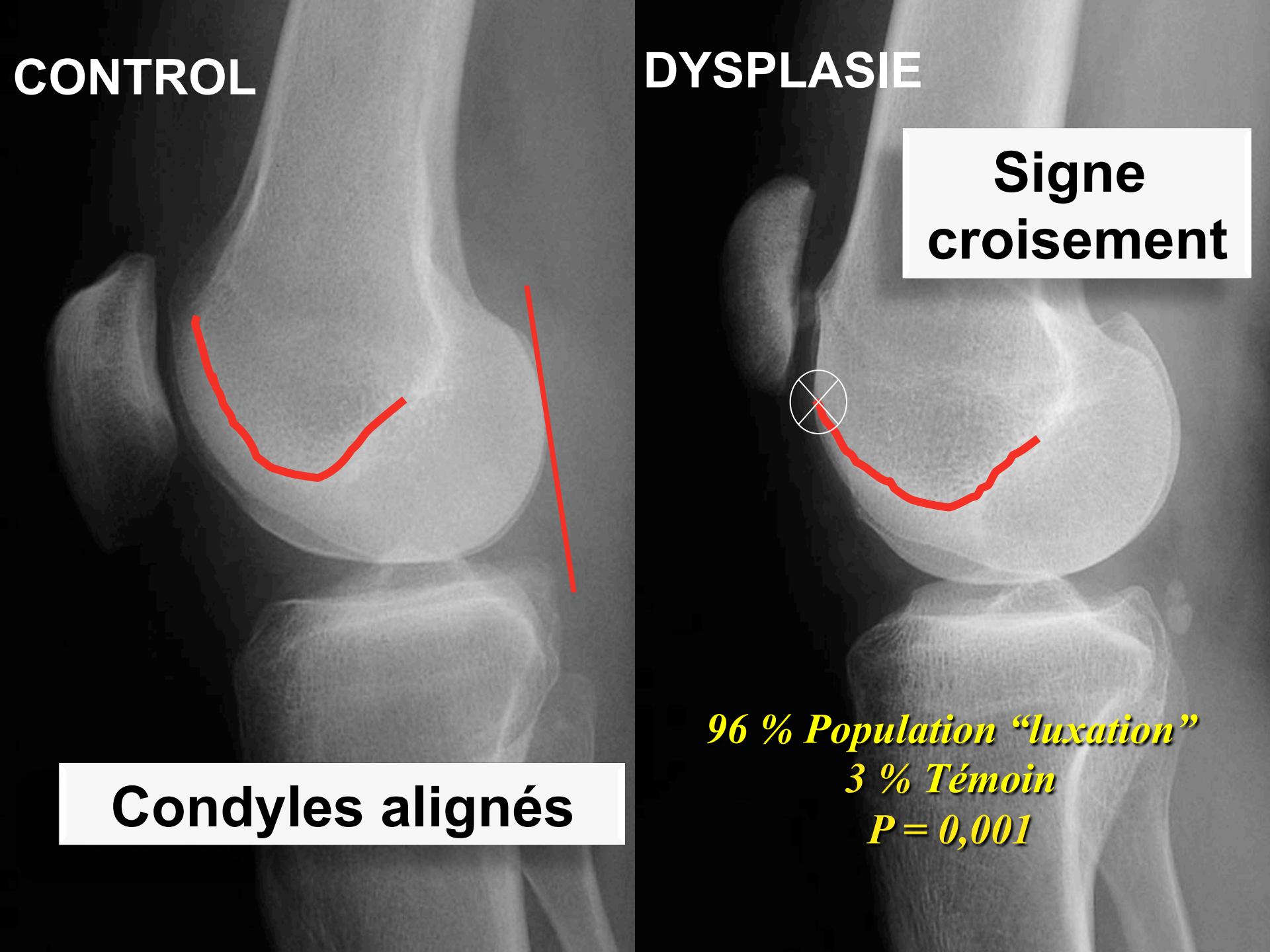
CONTROL
DYSPLASIE
Signe croisement
Condyles alignés
96 % Population “luxation”
3 % Témoin
P = 0,001

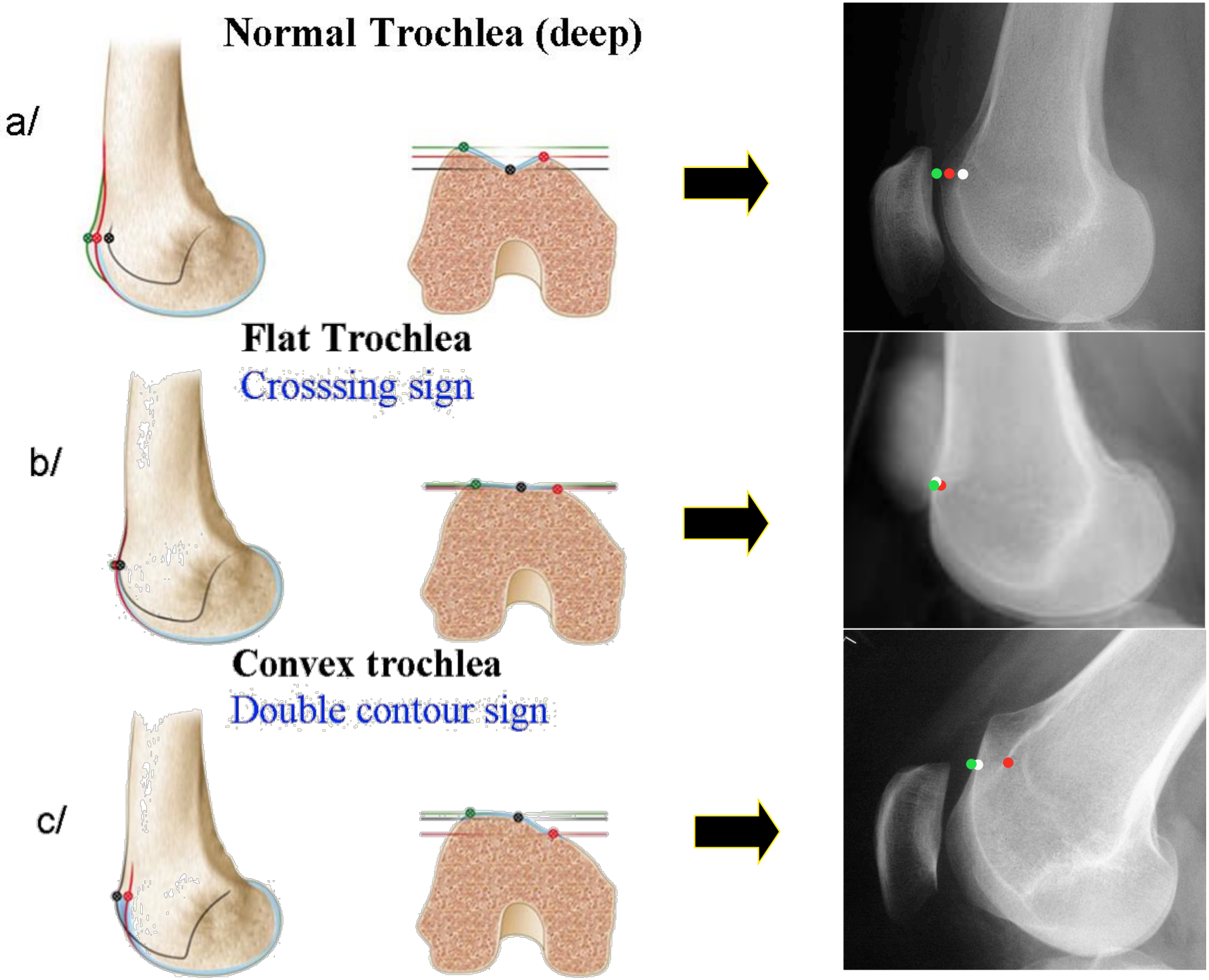
Normal Trochlea (deep)
a/
Flat Trochlea
Crosssing sign
b/
Convex trochlea
Double contour sign
c/

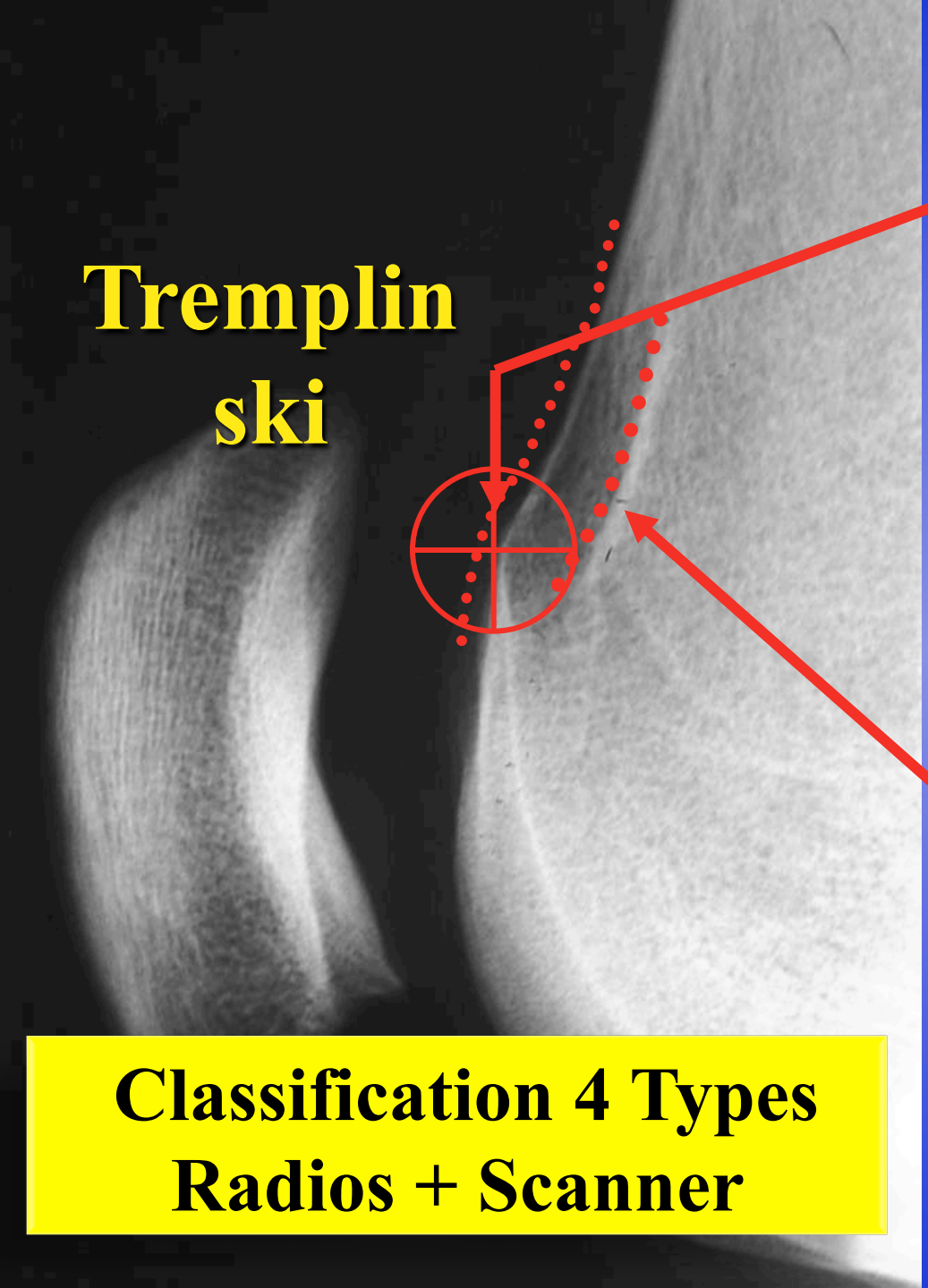

Eperon sus trochléen

+++

Signe croisement

91 %

Double Contour (Versant interne)

Classification 4 Types
Radios + Scanner

D. Dejour and coll French J.Orthop. 2000
J Radiol 2001,
KSSTA 2006,
Sports Med Arthrosc 2007

D. Dejour and All
J Radiol 2001,
KSSTA 2006,
Sports Med Arthrosc 2007

Trochlear dysplasia classification

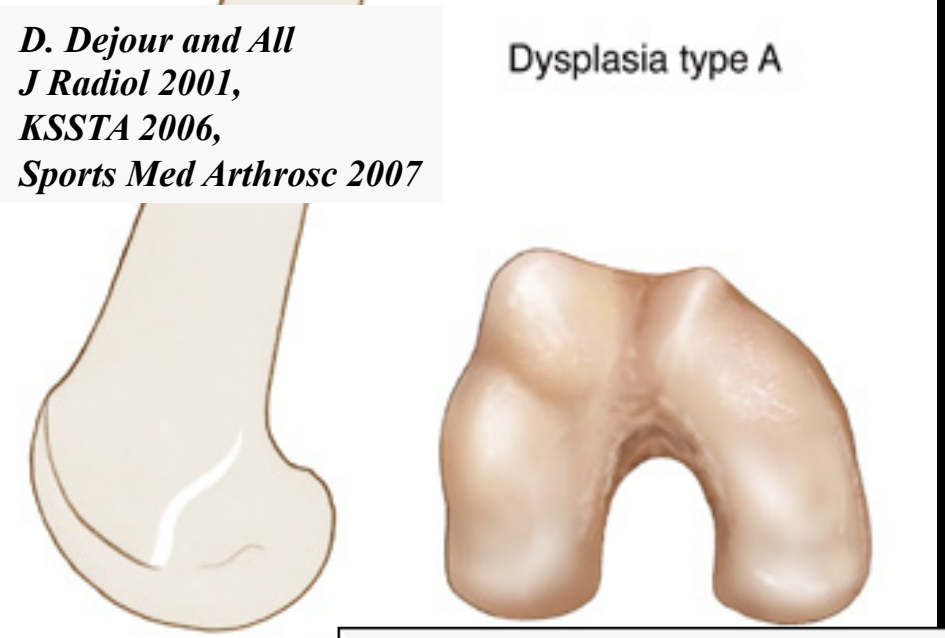

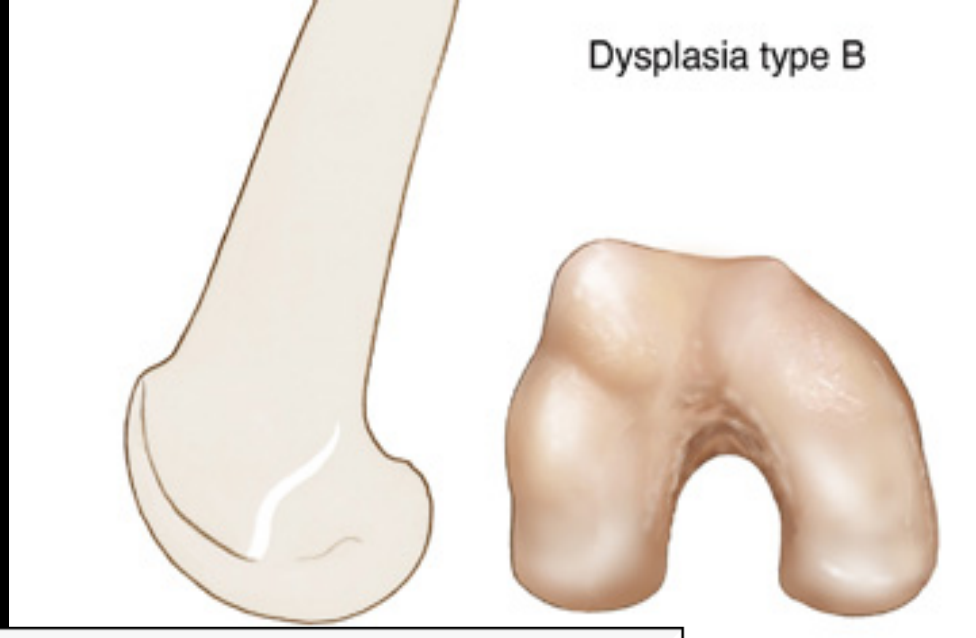

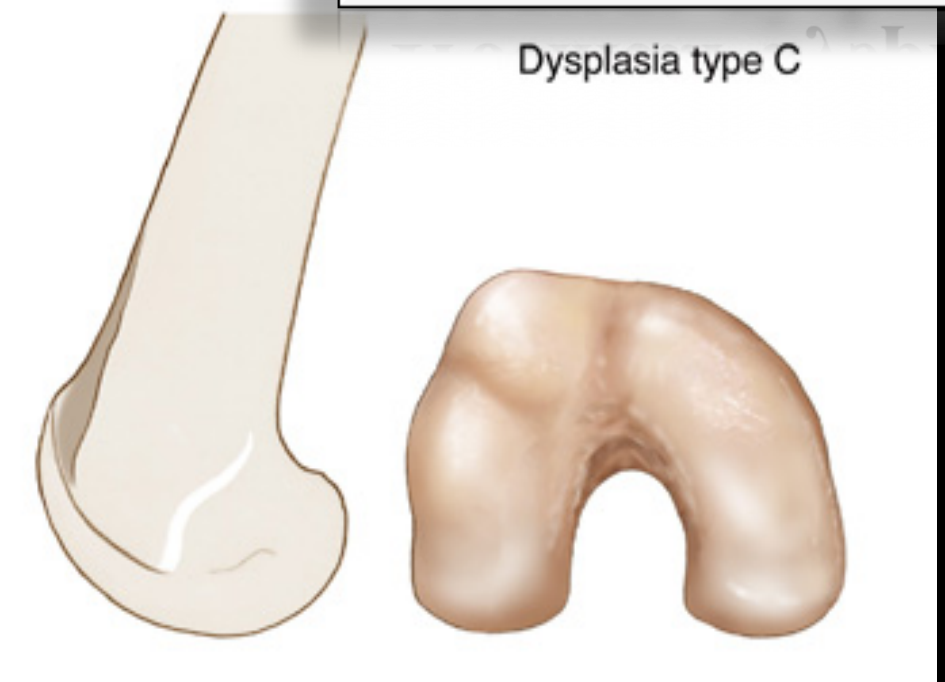

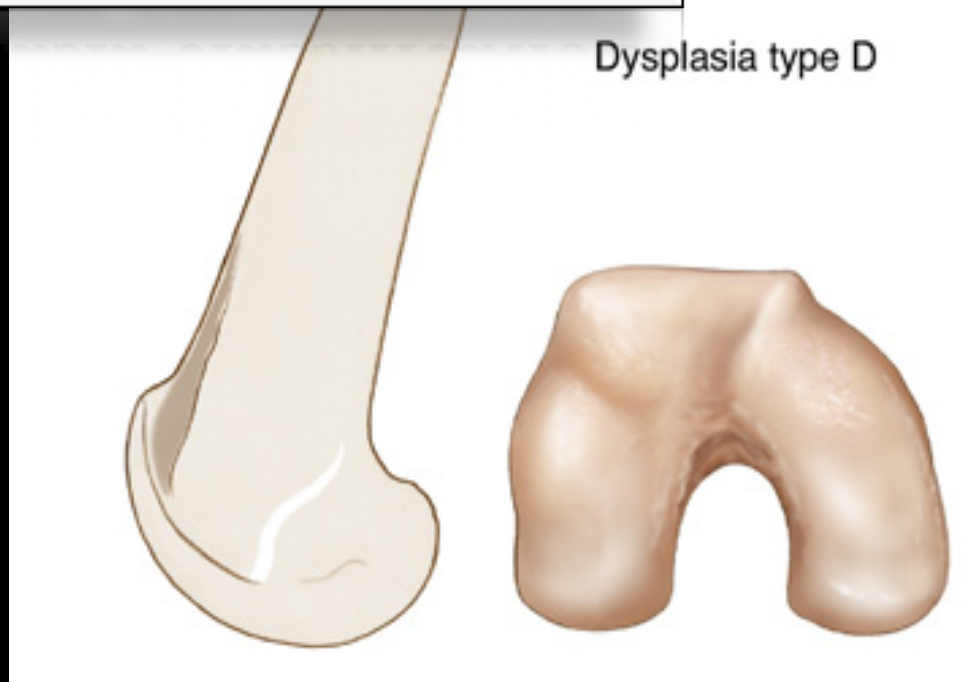

Grade A
54 %

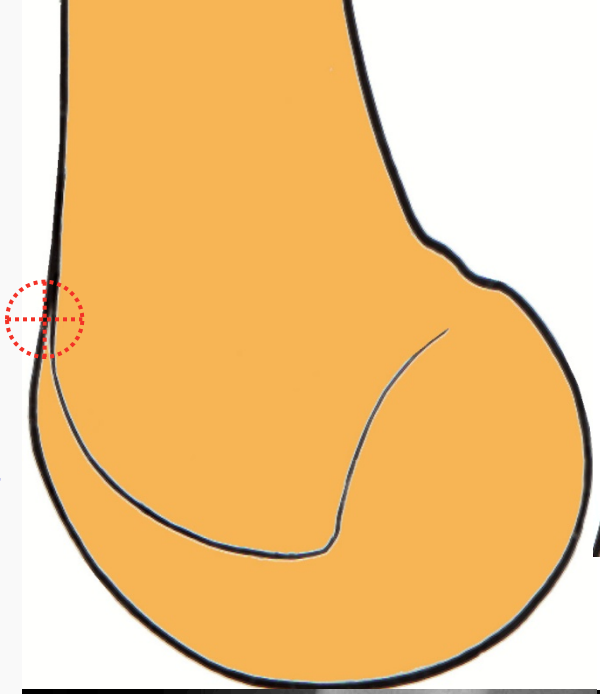

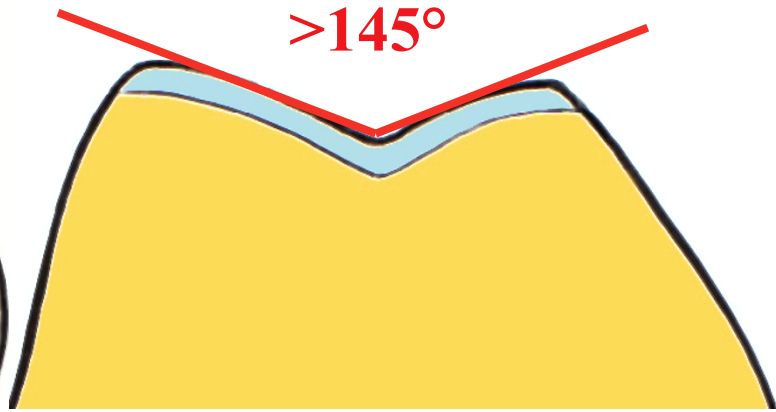

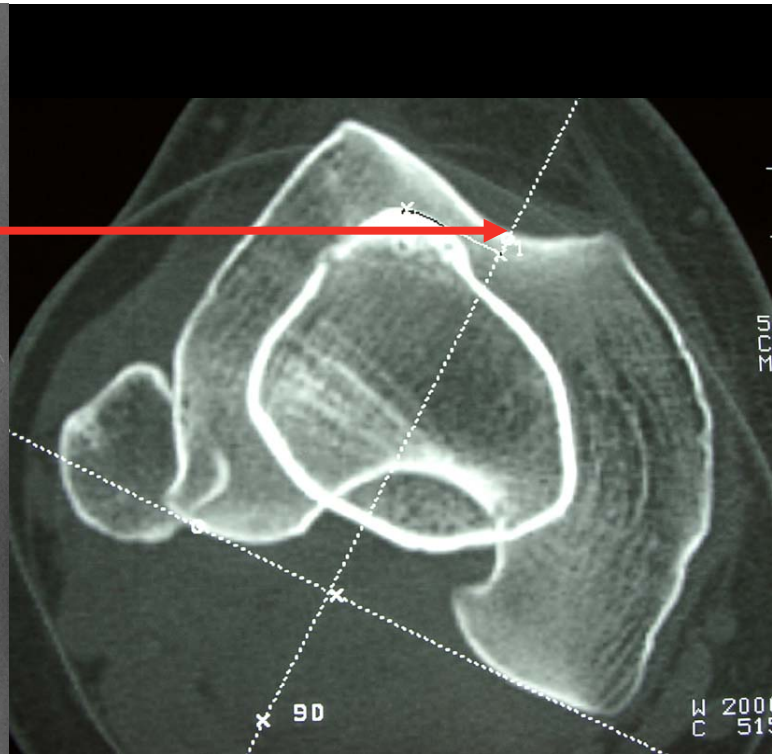

- Croisement
-Trochlée
peu profonde

Grade B
17 %

- *Croisemernt*
- *Trochlée plate*
- *Proeminence +++*

Eperon sus trochléen

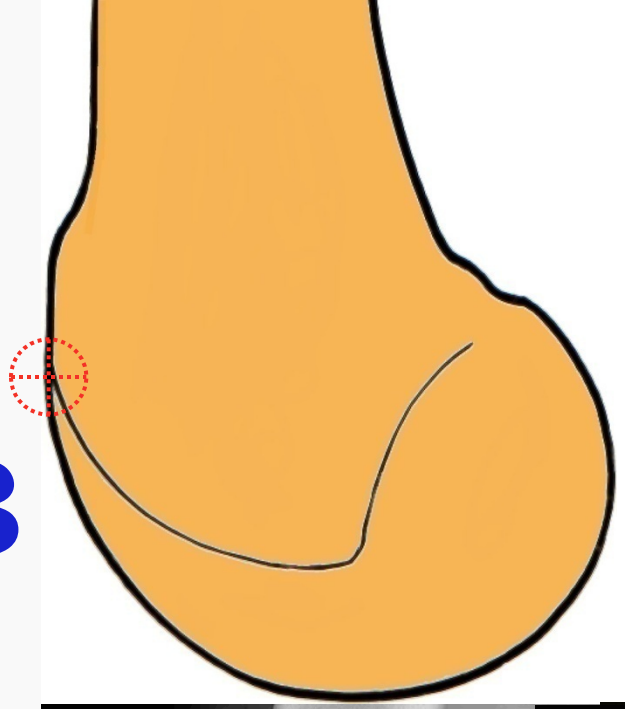

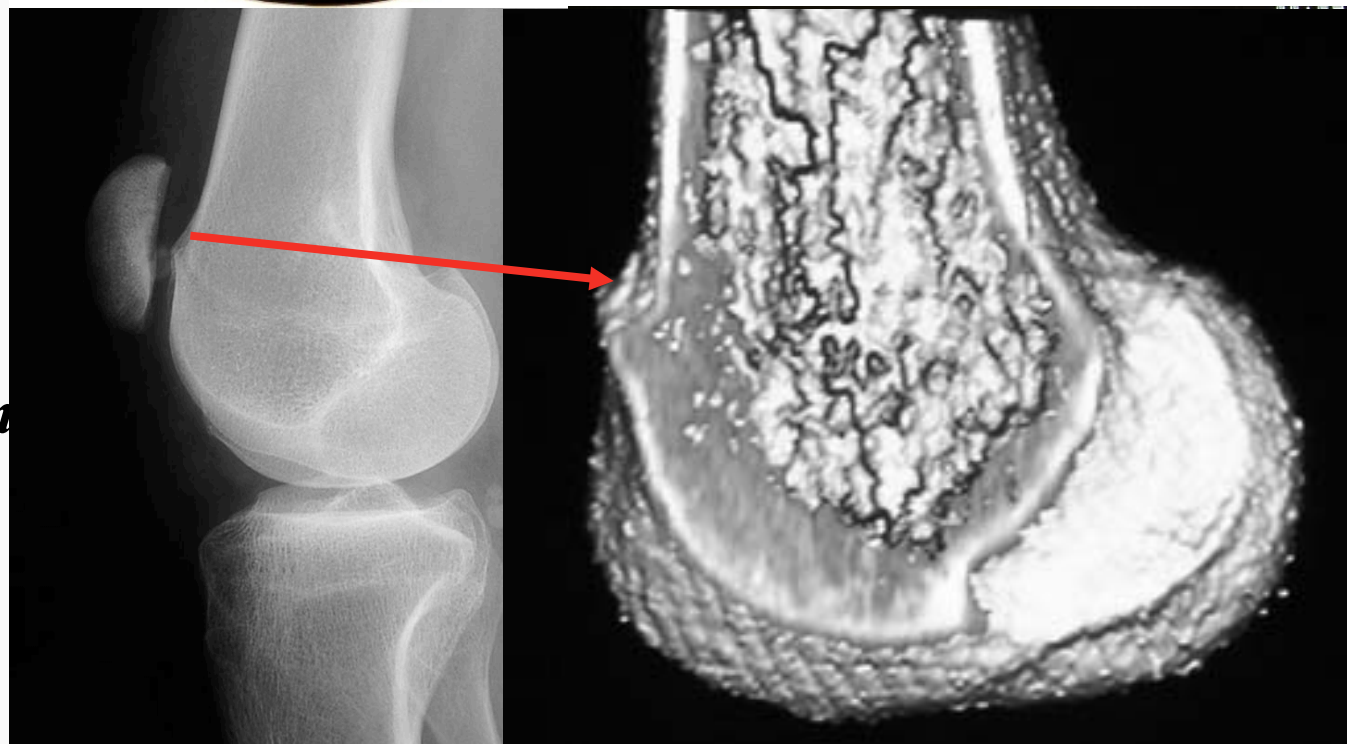

Grade C
9 %

-Croisement
-Double contour

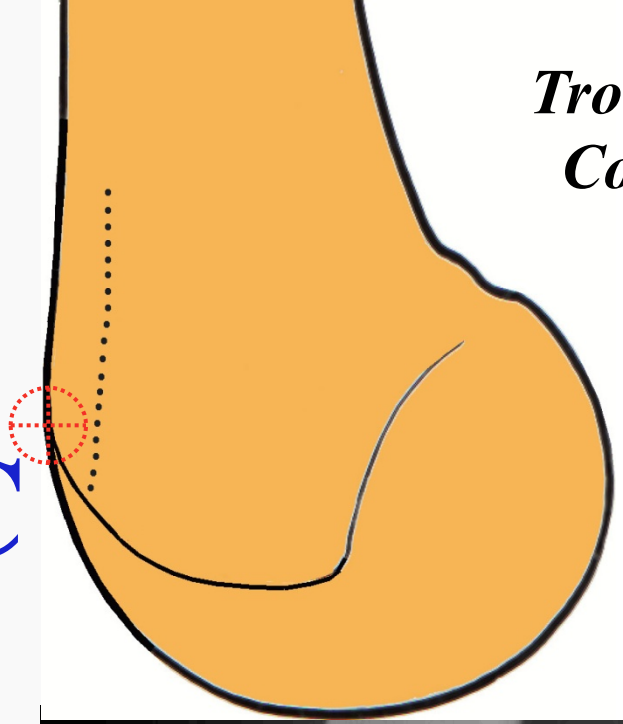

Trochlée externe
Convexe

Trochlée int.
Hypoplasique

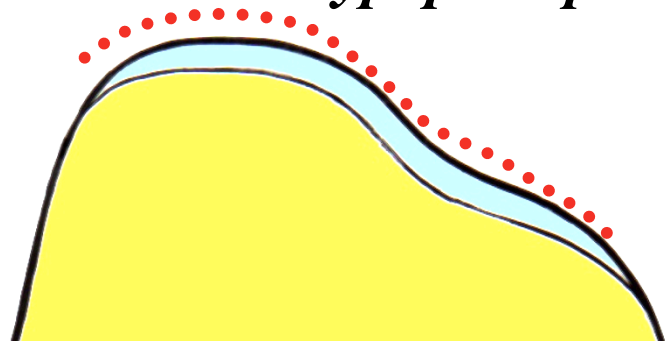

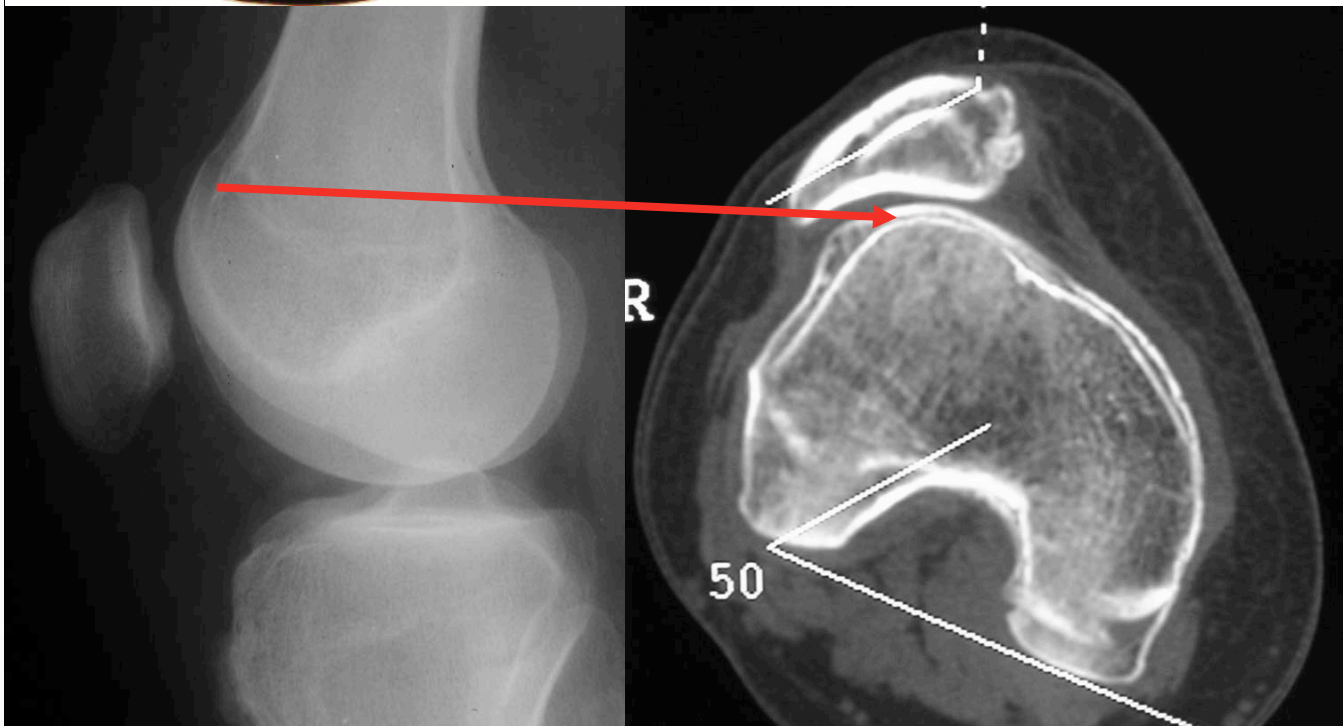

Grade D
11 %

- *Croisement*
- *Eperon sus trochléen*
- *Double contour*
- *Signe de la falaise*

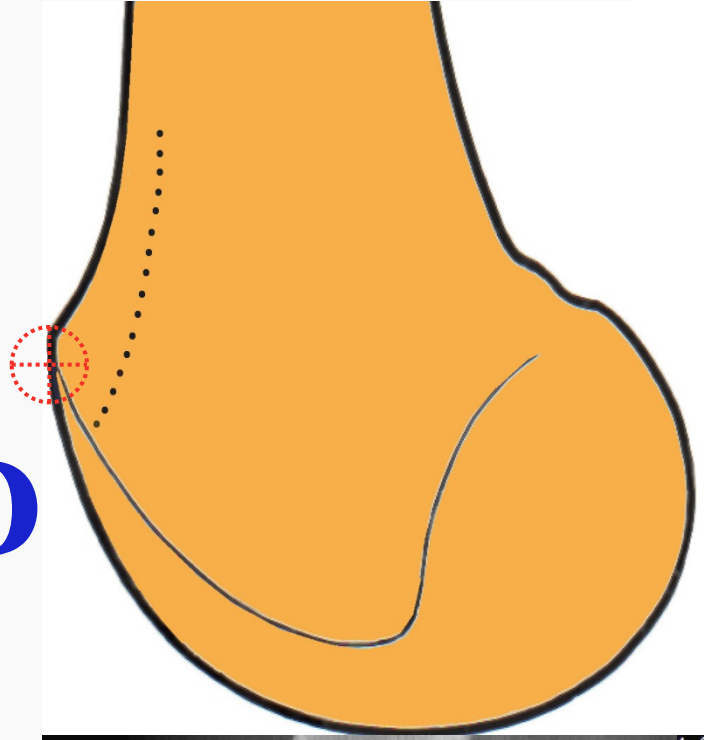

Signe de la falaise

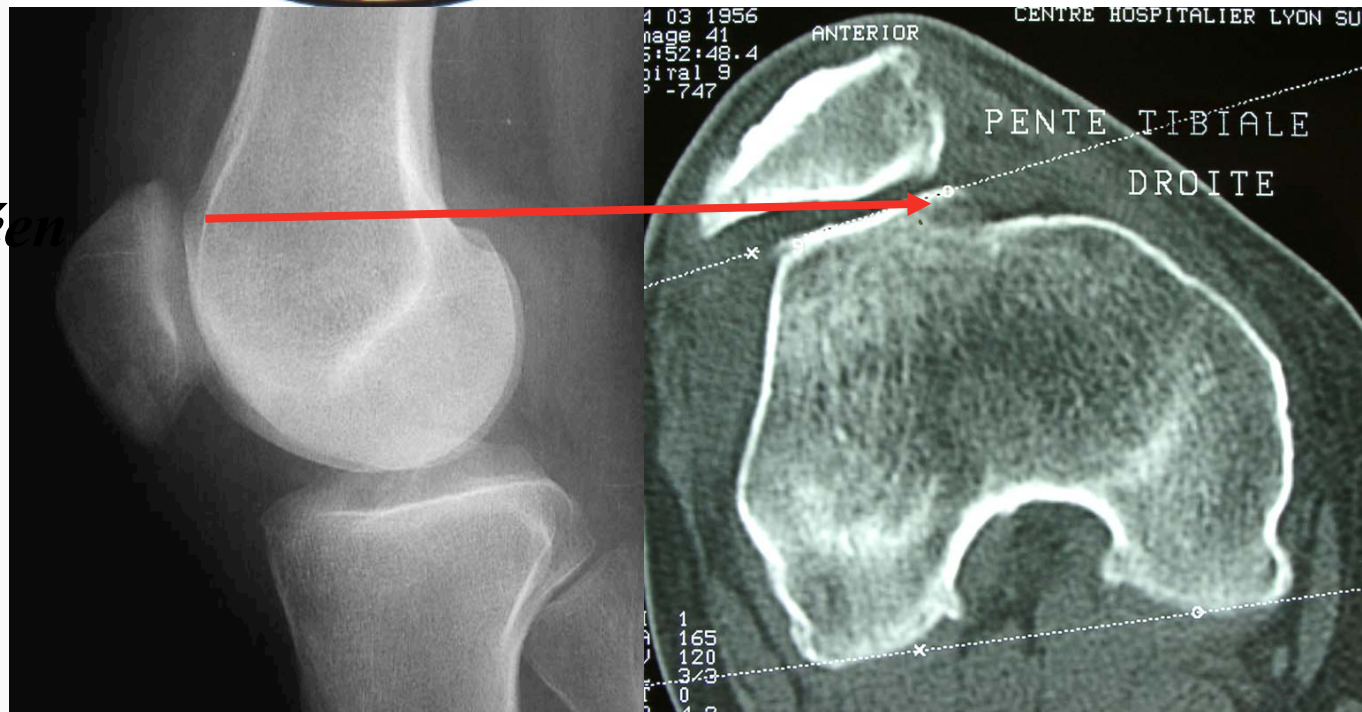

Meilleurs correlations

- Profondeur $p < 0,0001$
- Angle trochléen $p < 0,0001$
- Bascule rotule $p < 0,0001$

- Signe clinique $p < 0,0015$
- Nombre de luxations $p < 0,006$
- Douleur résiduelle après chir. $p < 0,005$

Dysplasie Rotule?

- Wiberg Classification

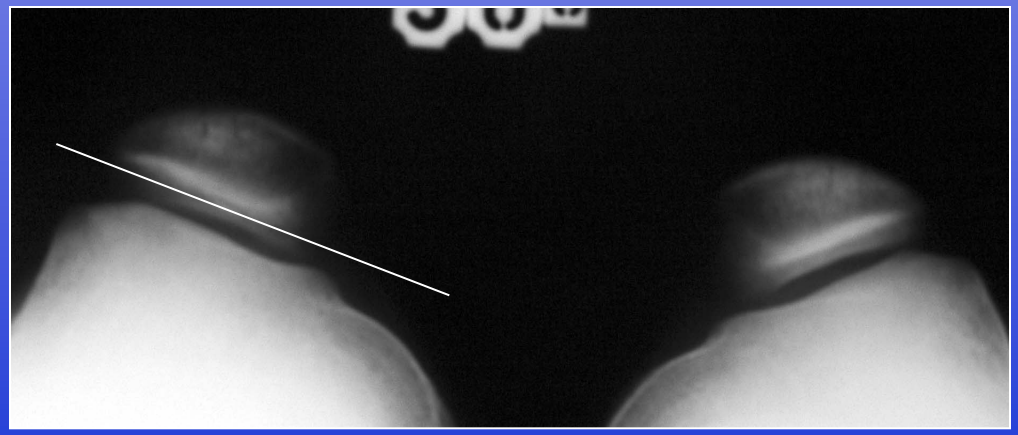

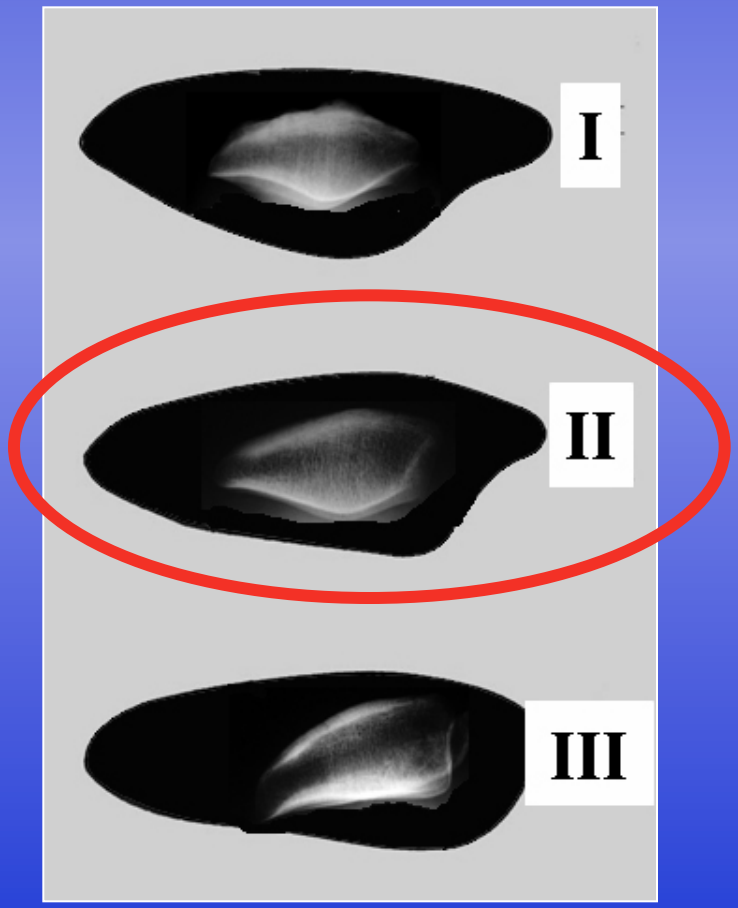

Vue axiale 30° Flexion

- Knutsson procedure , Merchant ...

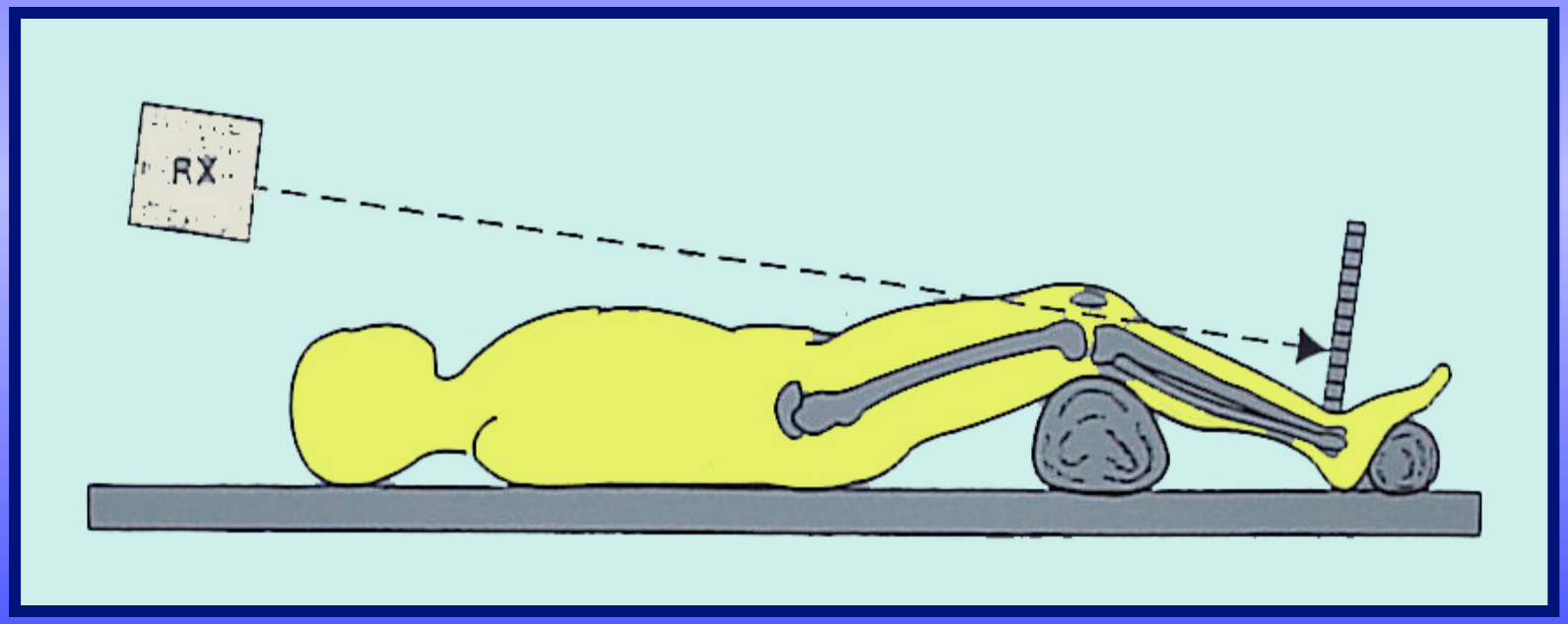

Montre partie supérieure de la trochlée

Angle trochléen
(dysplasie ≥ 150°)

Axial
View 30°

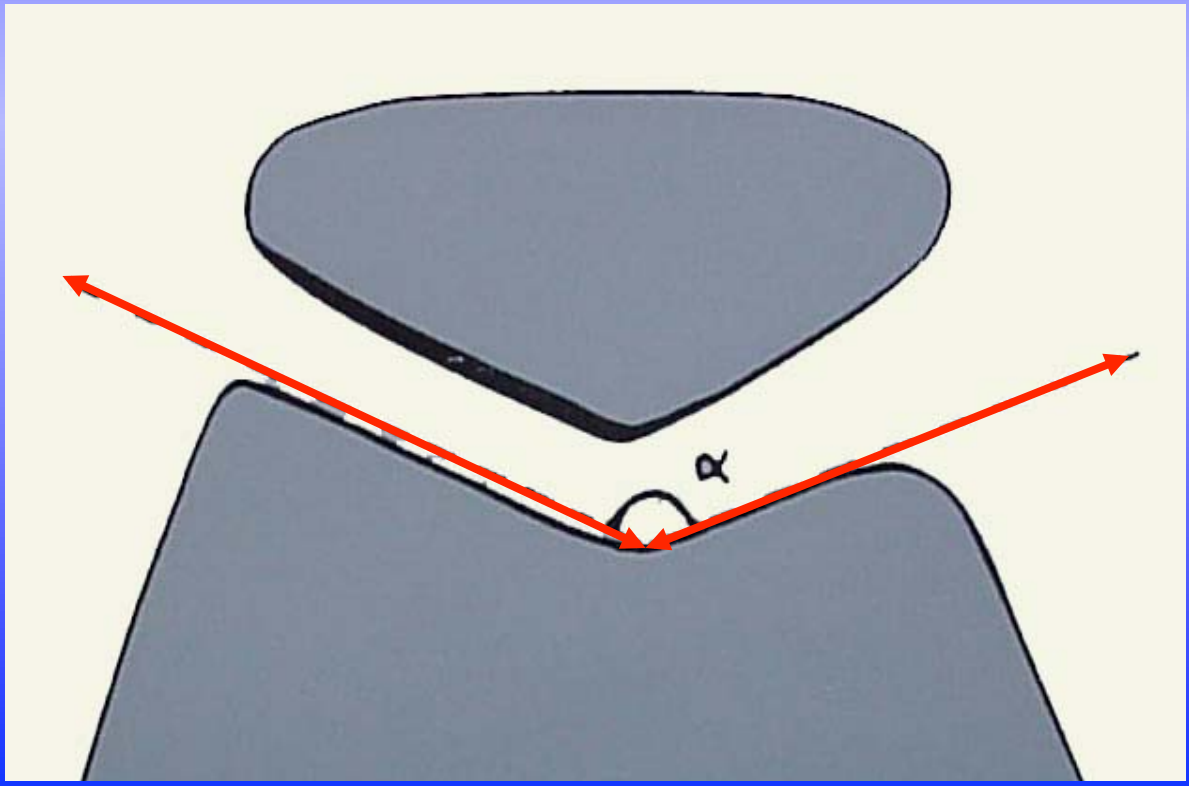

Vue axiale

Angle change
Avec le degré
De flexion

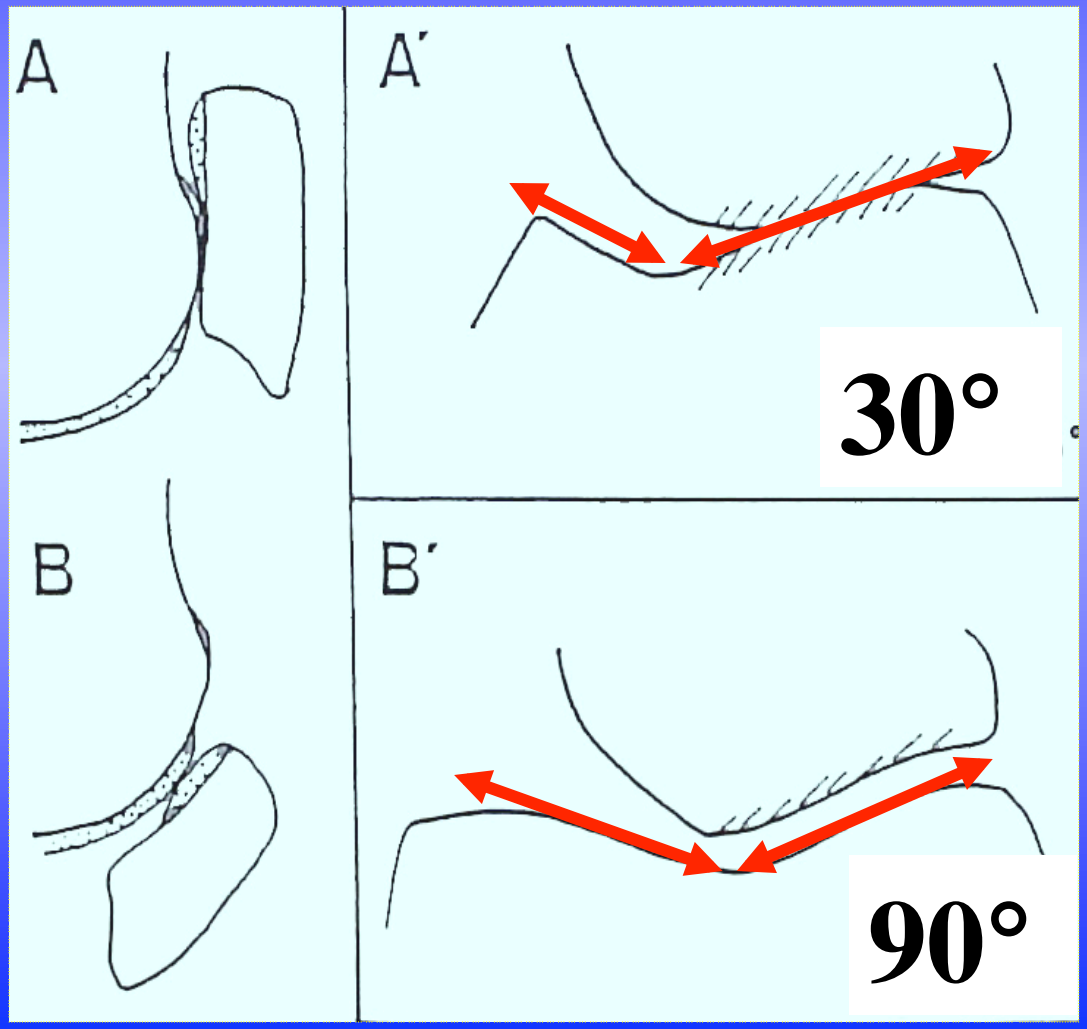

Vue axiale
Faux négatif

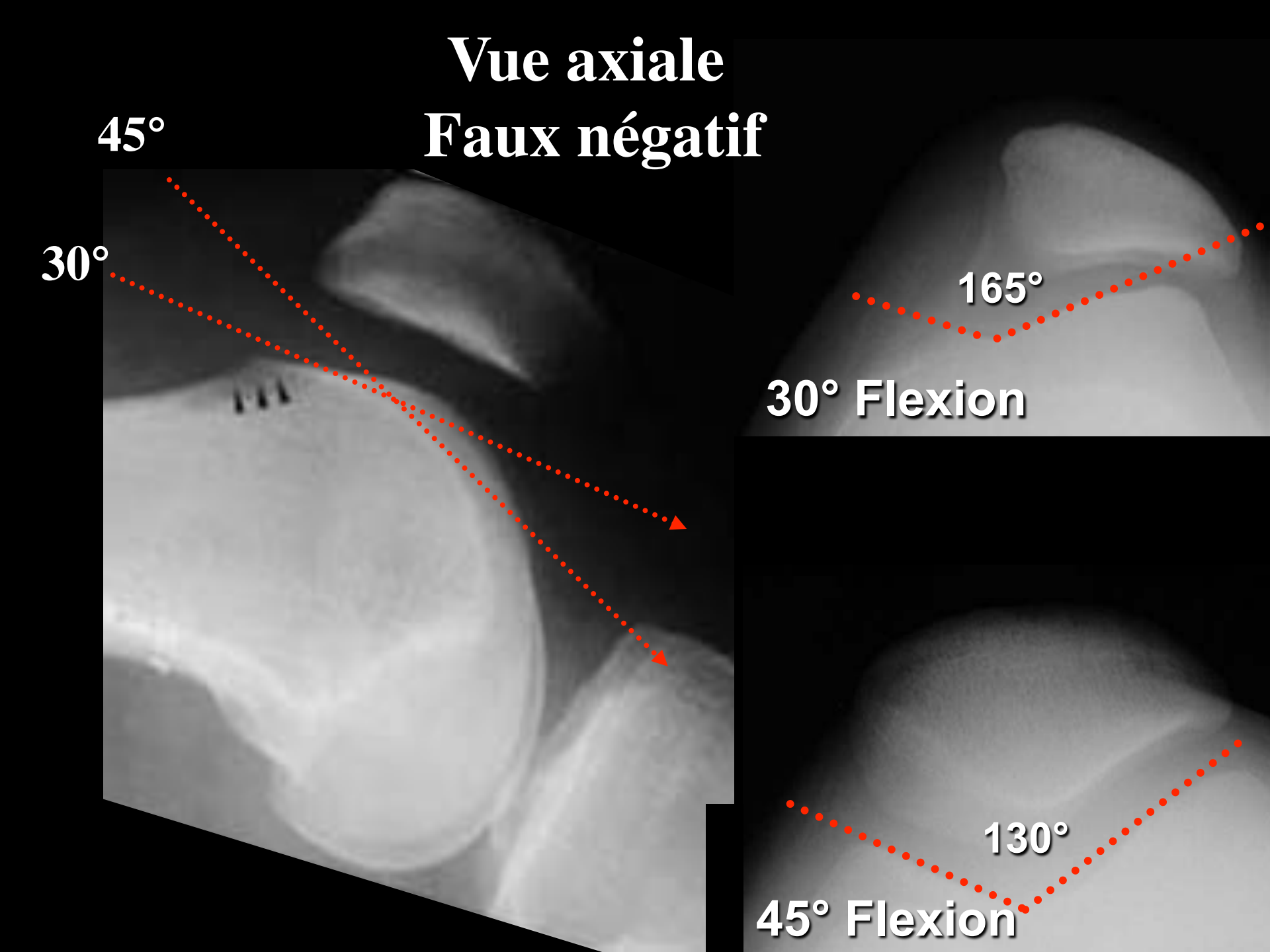

Patella Alta (Haute)

30 % population Luxation

Caton - Deschamps Index > 1,2

Témoin= 0 % P = 0,001

Rotule Haute

Témoin
0 %

> 1.2

Luxation
30 %

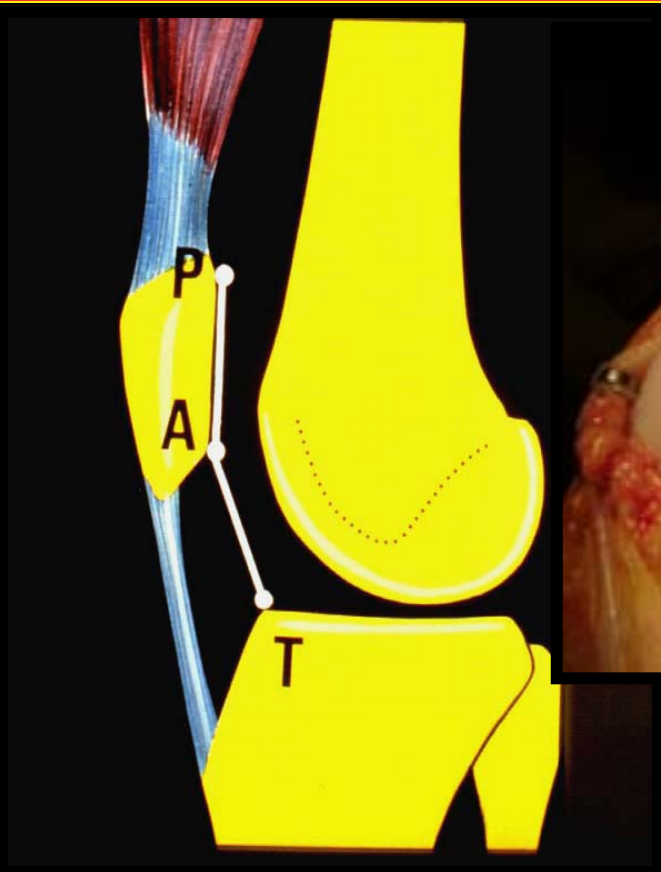

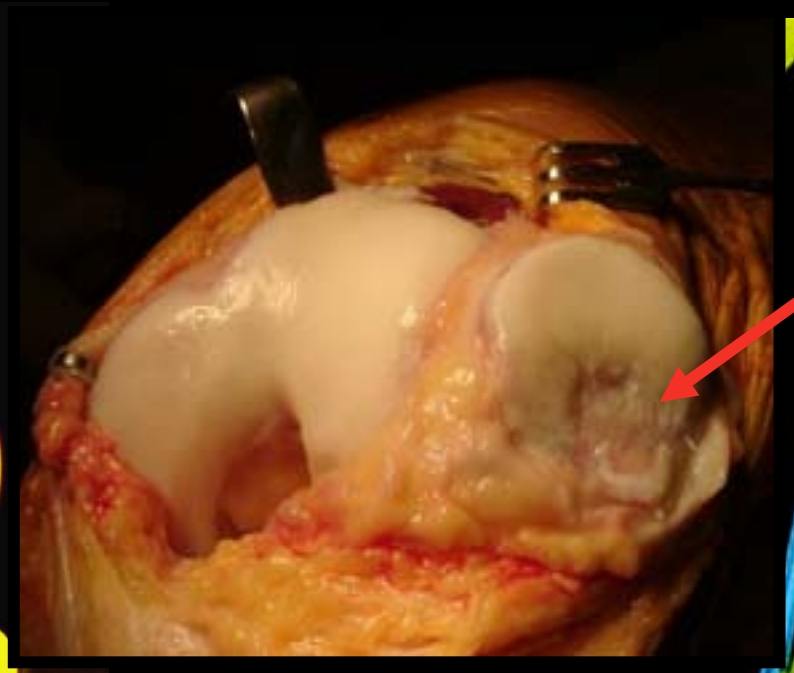

Hauteur rotulienne

- **Blackburne & Peel**

  Normal = 0,8

  Alta ≥ 1

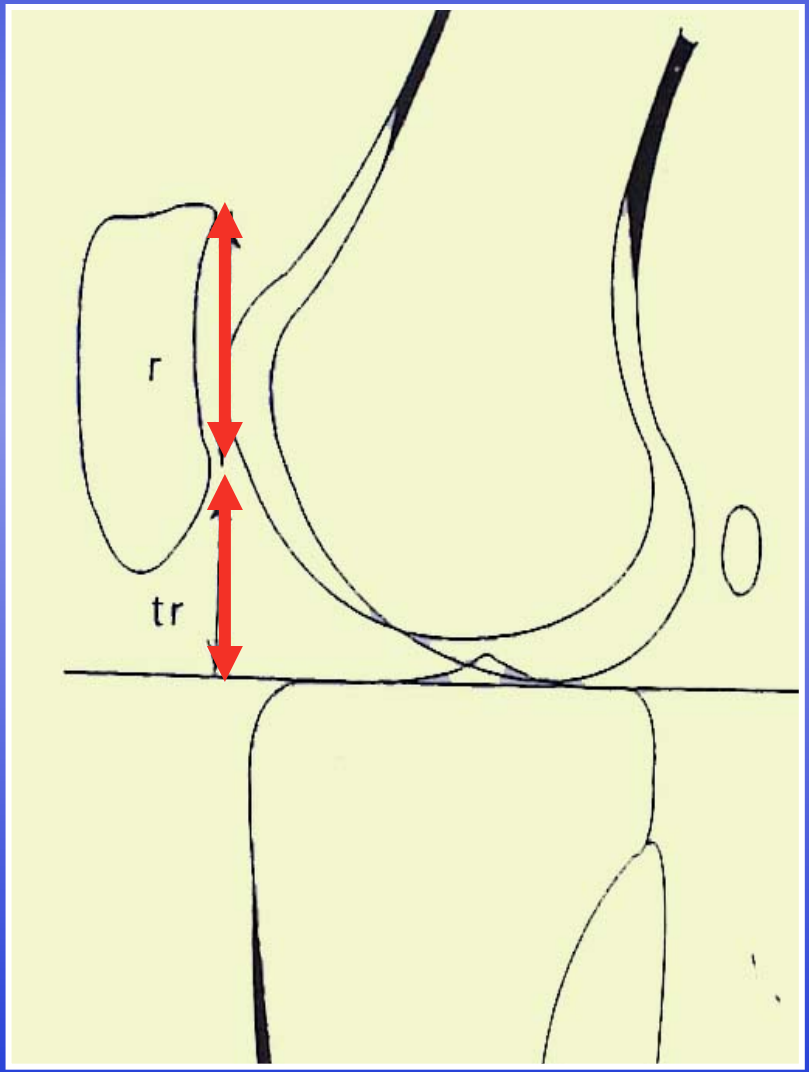

Hauteur rotulienne

- **Bernageau index**

Radio extension

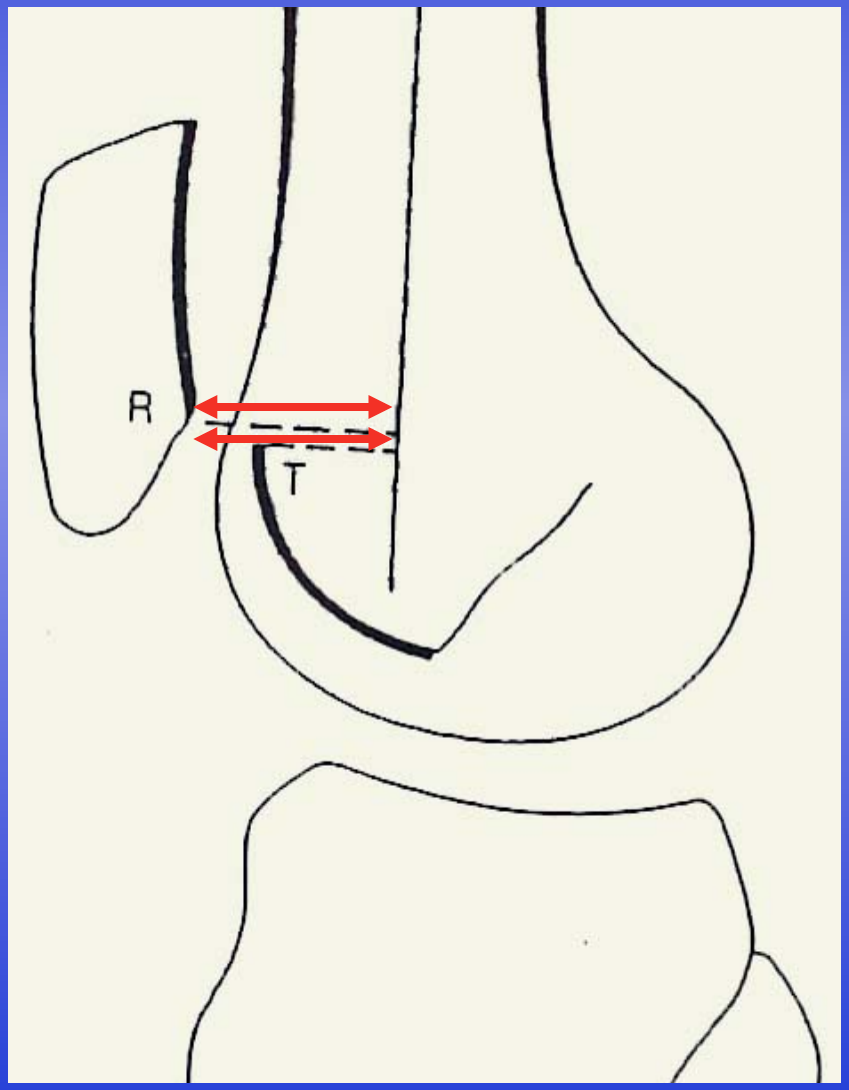

Hauteur rotulienne

- Scanner:

Pas de rotule en face de la trochlée

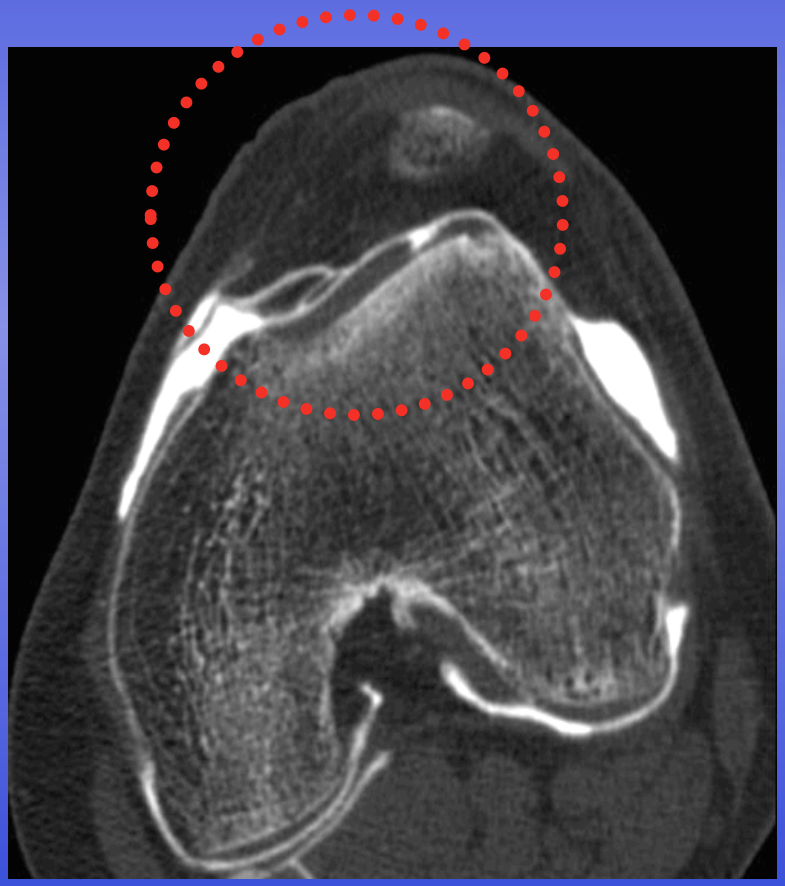

Hauteur Rotulienne

Longueur du tendon rotulien

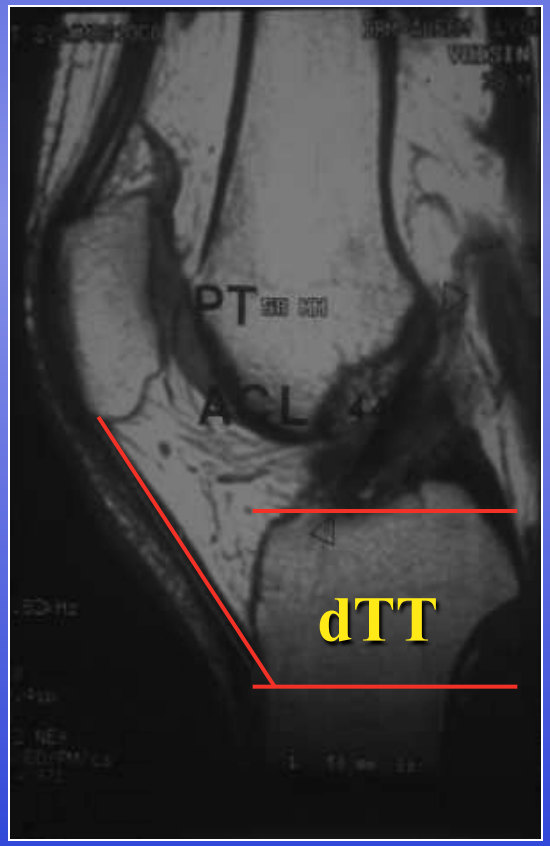

IRM

Neyret and Coll
Rev.Chir.Orthop. 2003

Tubérosité Antérieure – Gorge Trochlée

Evaluation Malignment

56 % > 20 mm
luxation
population

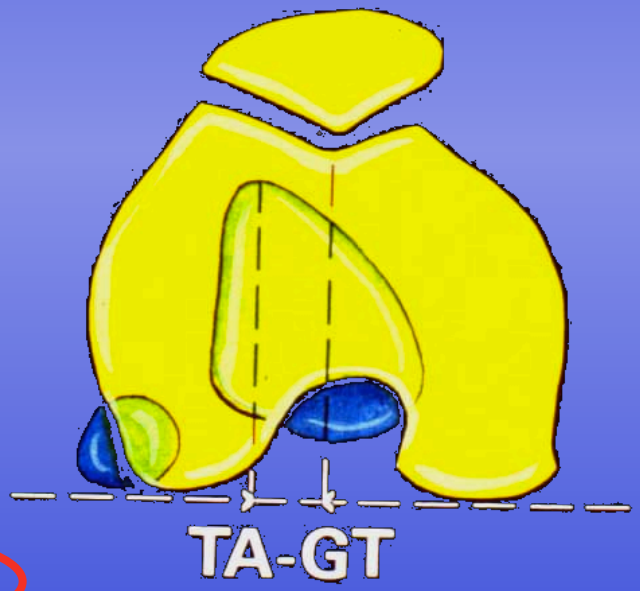

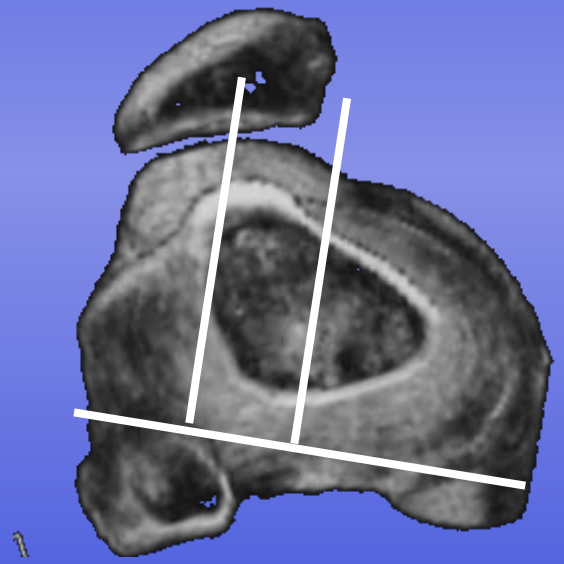

Control 12 mm P = 0,003

Scanner en extension

Goutallier 1978

CT Analysis

TA -GT

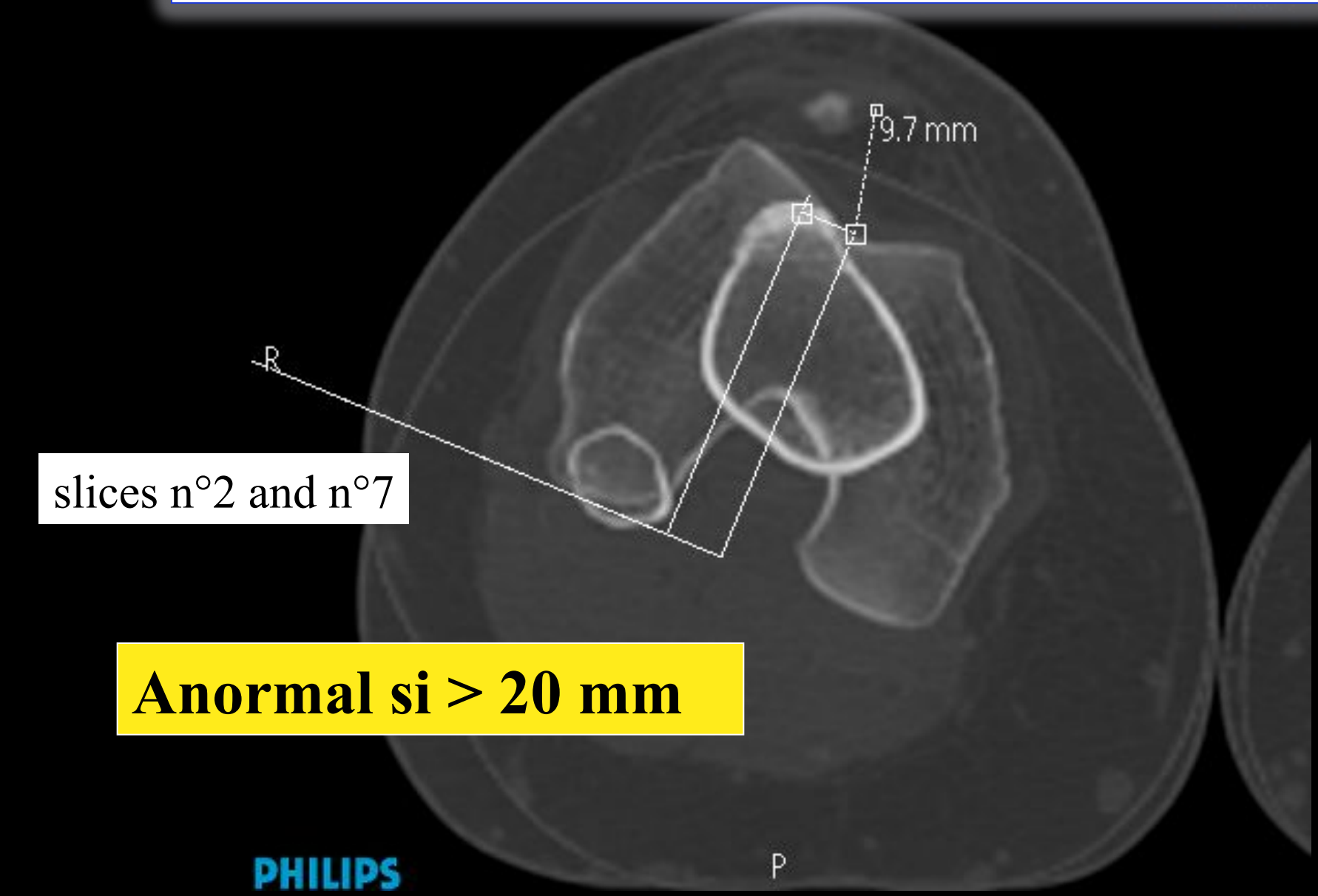

slices n°2 and n°7

Anormal si > 20 mm

TA - GT

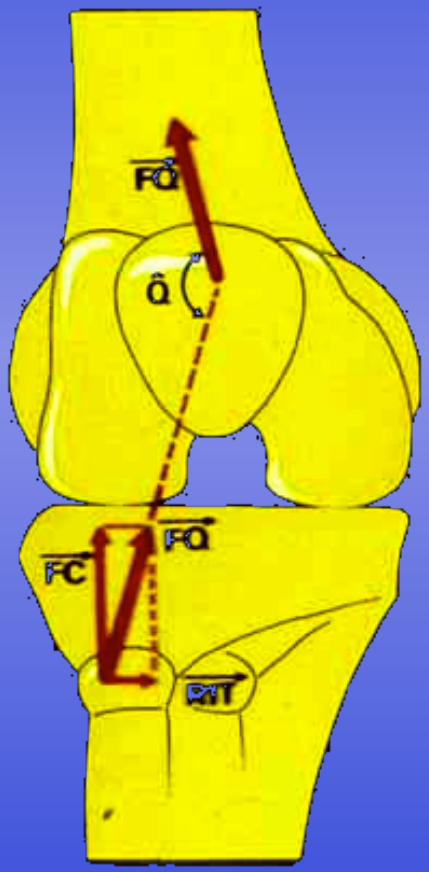

~~Angle Q~~

Bascule rotulienne

(Maldague, Malghem)

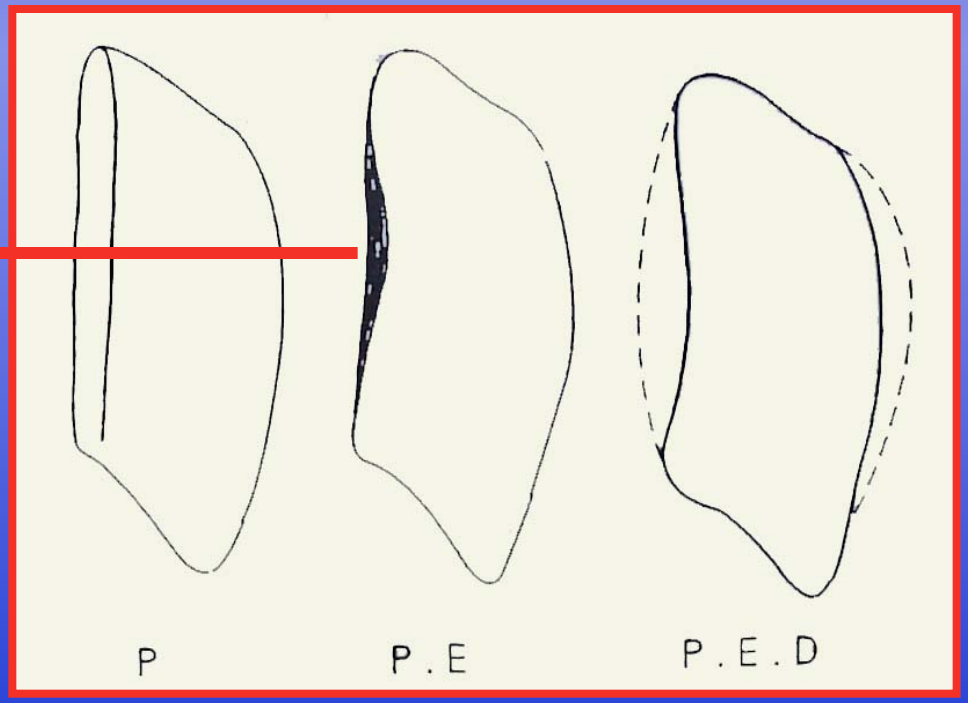

Analyse Scanner
Bascule rotulienne

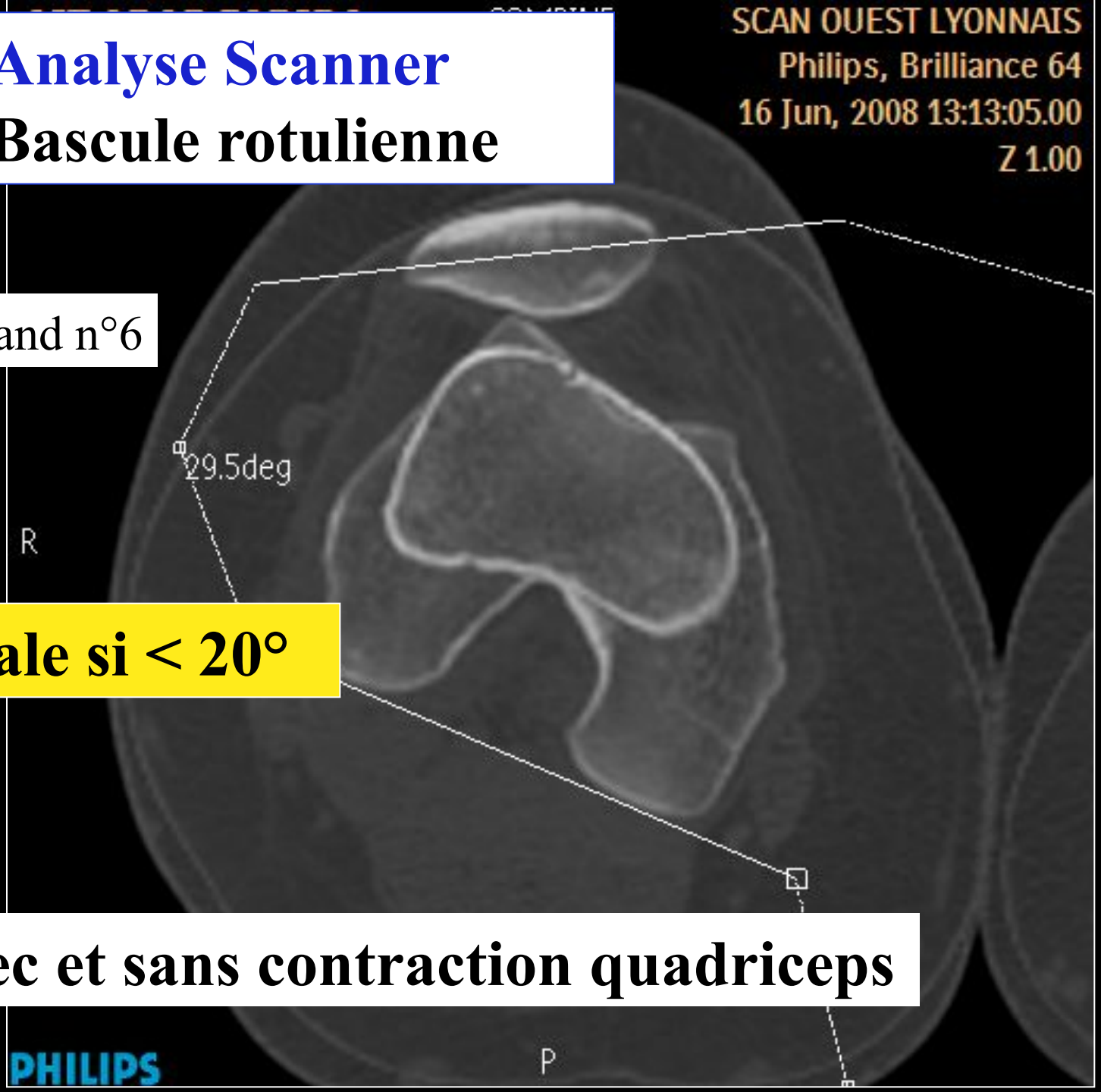

slices n°2 and n°6

Anormale si < 20°

Avec et sans contraction quadriceps

Bascule rotulienne

> 20° 83 % Luxation population

Témoin 3 % p = 0,001

Dysplasie vaste interne

Oui Mais...

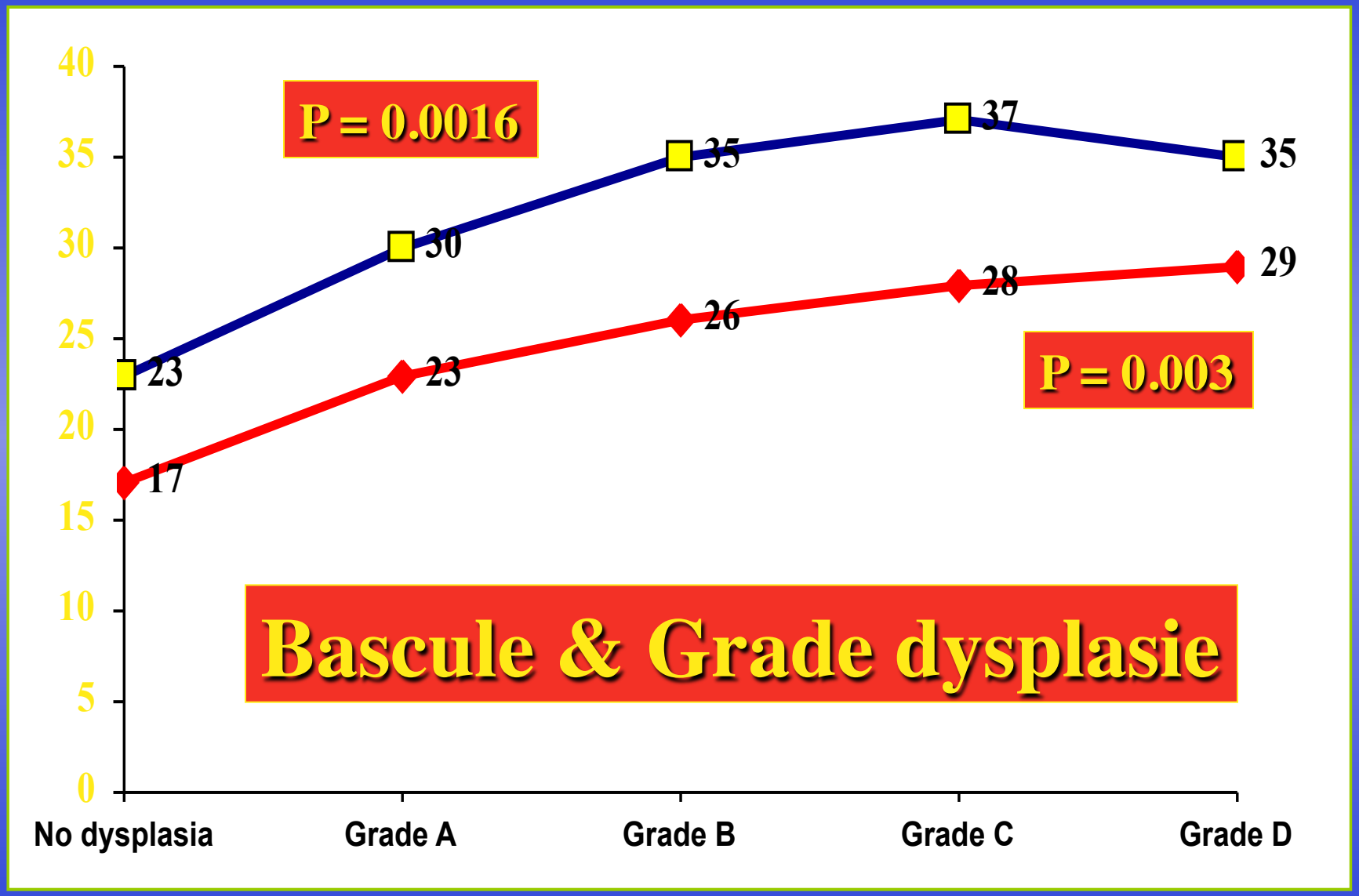
P = 0.0016
P = 0.003
Bascule & Grade dysplasie
40
35
30
25
20
15
10
5
0
23
30
35
37
35
17
23
26
28
29
No dysplasia
Grade A
Grade B
Grade C
Grade D

MPFL rupture ou distension



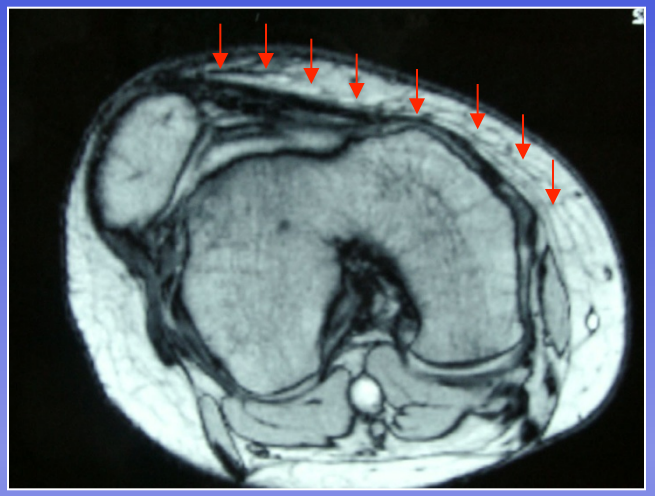

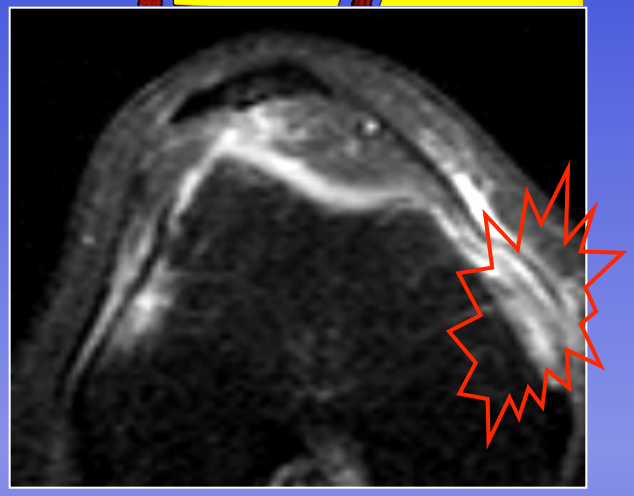

Phénoméne constant dans la luxation de rotule

Elle permet la luxation…

MAIS… C'est SEULEMENT une consequence

Ce n'est PAS le facteur initial

D. Fithian, A. Amis, E Arendt, P. Erasmus, J. Fulkerson …

Facteurs Secondaires

Pas de seuil statistique

- Genu Valgum
- Torsion excessives
  - . Femur
  - . Tibia
- Genu recurvatum

ClassificationPatient

Au moins une luxation

+

Anomalies radiographiques

- Dysplasie Trochlée
- Patella Alta
- TA-GT
- MPFL rupture = tilt

Instabilité Rotulienne Objective

Douleur PAS luxation

Radio standard normale

Instabilité Rotulienne Potentielle

Syndrome Rotulien Douloureux