



## PORTRAIT



David Dejour

*David Dejour should have finished his mandate as president last May 2020 in Milan, at the ESSKA congress. He tells us about the highlights of this very popular congress and retraces the main stages of his professional career, which is entirely focused on the knee.*

**David Dejour:** For the first time, we have organised the congress around a theme: «*When fashion meets science*». At first glance, the link does not seem obvious, but there are two possible interpretations.

The first, the simplest one: Milan, a fashion mecca, hosts ESSKA, which is a science-providing structure. But we can go further! Haute

couture is research based on the history of fabrics, shapes, materials and techniques, which leads to the ready-to-wear clothes that 'everyone' will use on a daily basis. We then find this common ground with fundamental research - industry - surgeons with the aim of improving the condition of our patients.

*(to be continued page 2)*

**MEG:** David, tell us about this year's ESSKA Congress 2021

### SUMMARY

- **PORTRAIT**  
D. Dejour ..... 1-4
- **PREAMBLE**  
One year ago...  
D. Dejour ..... 1
- **EDITORIAL**  
ESSKA Congress Issue  
M. Hirschmann, D. Dejour ..... 5
- **CONGRESS**  
ESSKA @ Home 2021  
"When fashions meets science"  
..... 6-7
- **TECHNIQUE**  
Fresh osteochondral allograft (FOCA) transplantation of the knee. A rare used technique in Europe with long term good results  
P. Gelber ..... 8-13

- **TECHNIQUE**  
Patients Specific Cutting Guides are helpful. Tools from simple to Complex Intra-Articular High Tibial Osteotomies  
C. Jacquet, P. Berton, M. Donnez, A. Sharma, K. Kley, A. Wilson, S. Cerciello, S. Parratte, M.Ollivier ..... 14-23

- **TECHNIQUE**  
The "functional knee phenotype concept" and its impact on the controversy of proper frontal alignment in TKA  
S. Hess, EL. Robertson, L. Moser, M. T. Hirschmann ..... 24-29

- **TECHNIQUE**  
A diagnostic algorithm for acute syndesmotic injuries or "high ankle sprains": history, physical findings and imaging  
S.A. Stufkens ..... 30-35

## PREAMBLE

### ONE YEAR AGO...

#### David Dejour

Yes, this interview was done a year ago... and since then so many "adverse events", as they say in medicine, have occurred.

I could do the same interview again at this point in time, but that would mean forgetting all the history that preceded what we had done to prepare for the ESSKA Milan 2020 congress. It would be forgetting the new things we wanted to put in place, cancelling the launch of our new projects which have since seen the light of day as time goes on and they were ready. I am thinking of

the core curriculum, **Women in ESSKA**, the **new JEO** and so many others... It would be minimizing the efforts of all the people who have invested in the **Milan 2020** which promised to be very successful in terms of participation, of the success of the industry.

Since then, ESSKA has been working with the old board and the new board led by Jacques Menetrey, our new president, to resist, invent and build a new adventure for which we were not prepared. We have not seen each

other face to face since February 2020, we have spent and continue to spend hours and hours in videoconference to keep ESSKA alive, to give our members what they expect from their Scientific Society. The staff led by Zhanna Kovalchuk, our congress manager Jenny Ennis, our Corporate Relations Manager Rik Bollaert, our new PCO KIT that we had to inaugurate and have been working hard to reshape this congress that was postponed twice and then transformed into a "Virtual Congress", a real first!



[www.mo-journal.com/eu](http://www.mo-journal.com/eu)

**MO:** How do you see the link between fashion and orthopaedics?

**D.D.:** The parallel between the world of fashion and the world of science is striking: We may think that the practice of our profession is independent of any commercial environment, but this is not entirely true. Indeed, when fundamental research opens up new perspectives, refines theoretical knowledge and thus finds new therapeutic opportunities, our industrial partners will be able to apply instruments, materials and techniques in collaboration with surgeons and researchers. It is our patients who will benefit most from this. Fundamental research is the haute-couture, surgical techniques and the products derived from them are the prêt-à-porter... it is also a nod to this new entity that I wanted in ESSKA "Women in ESSKA" which focuses on the promotion of women in a rather masculine world... you will see it will be a highlight of the congress.

**MO:** What do you think of these new trends that are taking place?

**D.D.:** I find this very positive. With each new «wave» or «fashion» the whole community is questioned again. There are disagreements on this or that subject, and everyone has to prove the correctness of their theory through new studies. This is a great catalyst for research! On the other hand, I think we should always keep a critical attitude towards the constant arrival of new products and techniques.

**MO:** Does a society like ESSKA have a role in disseminating information?

**D.D.:** Yes, this is the essence of a scientific society. Mission number one is to deliver unbiased information to its members. ESSKA pays

particular attention to the scientific programme of the biennial congress or its intermediate congress "Speciality Days" to deliver information that is objective and validated by studies with impeccable methodologies. ESSKA likes to give a voice to promoters of different trends. It is in these intelligent and constructive exchanges that our members will make their choice.

**MO:** What is the mission of a congress?

**D.D.:** The dissemination and updating of knowledge at the time of the event. Not everyone reads KSSTA, JEO, or the other top orthopaedic journals regularly. Surgeons unfortunately do not always have the time to keep up to date by reading peer reviewed journals. Instead, they are inundated with information through advertising, social media, video news platforms and the like. This is where scientific societies play their full information role during their congresses by giving an unbiased summary of what is happening in the world. Giving the "pros" and "cons" and all the elements.

**MO:** Are these controversies important?

**D.D.:** They are fundamental and it is a strong feature of the ESSKA congress to compare the past and the present, to look for differences and the most remarkable developments. We can then see that certain trends regularly resurface in a 'rebranded' form. This is where we come to fashion with the famous 'bell-bottoms' of the 70's becoming totally outdated, then giving way to slim fitting trousers, but again the 'bell-bottoms' come back, in a modernised form. I find it fascinating, these cycles of clothing and scientific fashion!

**MO:** You mentioned that, in a way, the industry commercialises the fruits of research. Isn't that a problem?

**D.D.:** No, on the contrary. The industry is an essential partner in our exercise and in our development. It is certain that each one defends its product range with its associated KOL (Key Opinion Leader) panels and sales force. It's a very stimulating competition for everyone, and we can see it in all areas of economic life, and we are no exception.

**MO:** How do you manage this balance between science and marketing?

**D.D.:** In our congresses we have two areas, the amphitheatres and the conference rooms where all the material presented has been selected by the scientific chairs according to very rigorous criteria. This is where the highlight lectures, keynote lectures, instructional courses, symposia, round tables and free paper sessions are given. The participants can therefore listen to what is "validated". The second area is the technical exhibition area where all companies have their stands, as well as their workshops which are of high quality but openly oriented towards the brand's products. In these two areas, everyone will find knowledgeable fulfillment.

**MO:** In this regard, how does the preparation of an ESSKA congress work?

**D.D.:** It's a lot of work, and requires many steps. You have to define a team of programme chairpersons and the people who are going to implement the programme according to the spaces of the congress centre. This is a huge task. Michael Hirschmann and Kristian Samuelsson are our two ESSKA programme chairs, and Elisavetta Kohn is our local Italian program chair. This edition in Milan is a bit special as it is the first time

we are working with our new PCO (Professional Congress Organizer) KIT.

**MO:** Did it have a big impact?

**D.D.:** Yes, absolutely, and in the right direction. We needed a new and innovative concept. KIT, which is based in Berlin, brought us new technology, especially in the way of submitting symposia and instructional course lectures, as well as abstracts. We wanted it to be more open to our members, more transparent and to reflect what our members want to see covered, or what they are working on. We set up an online platform where we called on all ESSKA members; this is democratic and very open, but it increases the selection work considerably: we received more than 280 proposals for symposia, 2000 for abstracts, and many submissions also for ICLs.

**MO:** The selection work must have been enormous?

**D.D.:** Yes. The task is overwhelming, as this data needs to be evaluated and organised by specialties and even sub-specialties. Then the programme chairs, the new PCO and ESSKA leadership worked closely together to finalize and balance the final program which is going to be amazing!!!

This year we are inaugurating a new lecture in honour of our co-founders. The «Eijar Erickson lecture» will focus on arthroscopy and sport and the new «Werner Müller lecture» will focus on clinical and anatomical issues. You will also discover the real history of ESSKA!

**MO:** ESSKA fulfils its information mission through its congresses, but it is also very active in the world of publishing, isn't it?

**D.D.:** We have our flagship journal, the Knee Surgery, Sports Traumatology, Arthroscopy (KSSTA) Journal, whose editor-in-chief is Jón

Karlsson. It has a good impact factor (3.2) and is one of the major players in orthopaedic scientific publishing. Jon Karlsson's policy is to take most of the articles that are submitted to us and make them even more attractive. The aim is not to increase the impact factor at all costs, but to promote the work produced by our members and those who like our journal; that is why the journal is very big, maybe even a little too big, but we still manage to highlight many articles on a wide range of subjects such as sports medicine, all-round arthroscopy, degenerative knees, etc...

**ME:** But there is another journal attached to ESSKA?

**D.D.:** Absolutely. We also created in 2013 the Journal of Orthopaedic Experimentation -JEO- which Henning Madry was in charge of; it was an open access journal focused on basic science. The journal is indexed and should have an impact factor this year. But since basic science is not a broad subject, we ended up with an imperfect balance between the huge KSSTA with a wealth of very good scientific articles and an open mind, and the JEO which was making progress but was struggling to get off the ground. We decided to change the shape of JEO to 'New JEO', with a new editor, Stefano Zaffagnini, and a new editorial line. With Henning Madry leaving to take over the management of Osteoarthritis and Cartilage Open, he has done a remarkable job.

**ME:** Has the new JEO changed direction?

**D.D.:** We have kept basic science, which remains a fundamental element, but we have opened JEO to clinical work such as degenerative and sports knees, shoulders and ankles. The editorial team is made up of associate editors specialised in each field. This provides us with a very high level of expertise, rapid review and high quality. With these

changes we hope to restore the balance between KSSTA and JEO.

**ME:** Publishing is a big job for ESSKA?

**D.D.:** Indeed! Between the journals and the books, it is a considerable workload. We also have our newsletter, which went from a biannual print format, to a quarterly digital format, and is now a monthly publication called the ESSKA Times. This has allowed us to increase the volume of scientific articles and to broaden the scope of the content, in a much more timely format. It is an excellent tool for promoting and disseminating information, as it is distributed to the entire ESSKA family, which is about 10,000 people.

We are also extremely happy to be able to benefit from this collaboration that you offer us with MO journal. It is such a positive initiative and I can only be happy to see our former "Maîtrise Orthopédique" taking a European and even international path. Congratulations to you for your editorial quality!

**ME:** Is it difficult, with all these projects and this big machine that is ESSKA, to keep a certain consistency?

**D.D.:** We are working hard to maintain an "ESSKA spirit". This requires men and women who are motivated by a common spirit. The leadership of a company is its quality. First of all, there has to be continuity in the board and in the presidential line so that the work is not started from scratch every two years, with each change of president. Since 2010, we have organised a strategic meeting every two years, which allows us to define lines of action for two, four and six years. The continuity and follow-up of projects is fundamental. I have continued the work of Romain Seil, Jacques Menetrey will continue what I have put in place, and then it will be Roland Becker's

turn... these are not names in front of actions but a group, a team that speaks only for ESSKA. There is no room for individualism.

**ME:** In terms of education, what are ESSKA's plans?

**D.D.:** The list is long between the biennial congress, the Speciality Days which take place in the year when there is congress and deals with the very specialised subjects of the ESSKA Sections (degenerative knee, arthroscopic ankle and shoulder and sports.)

There are also the books that are published every two years for our participants, the ESSKA academy which is a platform where you can find the main conferences of the congresses and videos of surgical techniques.

**ME:** There are also cadaver courses?

**D.D.:** Yes, we have reorganised our courses to change the format. We call them "All about..." it's like an ESSKA trademark. The participants have a day and a half of intensive training on a highly focused topic. If they take part in an "All about ACL", they will know everything about the anterior cruciate from grafting, associated injuries, menisci, osteotomies, etc. This formula is very successful.

**ME:** What is the model?

**D.D.:** It is simple and is done in partnership with the companies who also have this concern for education. The programme and faculty are defined by ESSKA and we go to the companies' cadaver labs. The business model works well and allows us to have a reduced cost for our participants, and the faculty donates its fees to the ESSKA Foundation. It is also an excellent way for our partners to promote their equipment as we use what they have on the market. We would like to thank them for this win-win partnership.

**ME:** You also wanted to create an "ESSKA" certification?

**D.D.:** The idea was born in our 2016 strategic meeting led by Romain Seil. We asked Martin Lind, our educational secretary, and an external consultant hired by ESSKA, Michael Ross, to work on a methodology to define what a certification is and what criteria are needed in each area to be considered certified. We brought together a group of experts in each area to define these items.

Launched in May 2020, this modular competency-based core curriculum is based on both theoretical and practical knowledge, to define the core competencies required by ESSKA specialists. It consists of 285 Core Competencies, which have been arranged into ESSKA's six Specialist areas: Knee, Shoulder, Foot & Ankle, Hip, Elbow & Forearm, and Sport & Exercise.

**ME:** It's a great project, how long did it take to come to fruition?

**D.D.:** The process took over three years. That is the point of these strategic meetings, which handle the medium and long term. In two years, a president cannot complete all the projects, and we have to organise the continuity and transmission of projects from one presidency to the next. This is the great strength of a team that works towards a common goal: ESSKA.

This work is very consistent and strengthens our identity.

**ME:** Let's talk about you. You are French and live in Lyon. Does the city have a particular relationship with ESSKA?

**D.D.:** Let's talk about France first. I would be so happy to see more French people in the international congresses. This is probably due to the very good offer produced by our national societies SFA, SOFCOT... but I would encourage our young colleagues to travel, it is so enriching... If you speak English you will make your

21, Rue de la Ravinelle  
F-54000 Nancy  
Tel : +33 (0)9 72 21 11 73

[www.mo-journal.com](http://www.mo-journal.com)  
[abonnement@maitrise-orthopedique.com](mailto:abonnement@maitrise-orthopedique.com)

ISSN : 2658-9877

**EDITORS IN CHIEF**

Hofmann S. (Vienna)  
Lustig S. (Lyon)

**SCIENTIFIC COMMITTEE**

Argenson J.N. (Marseille)  
Bellemere P. (Nantes)  
Benedetto K. (Innsbruck)  
Boileau P. (Nice)  
Dejour D. (Lyon)  
Doursonian L. (Paris)  
Flurin P.H. (Bordeaux)  
Gregory T. (Bobigny)  
Kerboull L. (Paris)  
Landreau P. (Dubai)  
Laude F. (Paris)  
Masquelet A. (Paris)  
Métaizeau J.D. (Dijon)  
Nelissen R. (Leiden)  
Neyret P. (Lyon)  
Parratte S. (Abu Dhabi)  
Pasquier P. (Troyes)  
Perka C. (Berlin)  
Pfeil J. (Wiesbaden)  
Scheibel M. (Berlin)  
Tourné Y. (Grenoble)  
Trnka H-J. (Vienna)  
Romano C. (Milan)  
Van Hellemond G. (Nijmegen)  
Walch G. (Lyon)  
Zeller R. (Toronto)

**GENERAL MANAGER**

Melison O. (Nancy)

**Printed by :**

IMPRIMERIE MODERNE  
[www.imprimeriemoderne.pro](http://www.imprimeriemoderne.pro)

**Photo cover credit**

©Janifest/123RF.COM

*The articles published in MO Europe are published under the only responsibility of their authors.*

*All rights of translation, adaptation and reproduction by all processes reserved for all countries.*

research shine internationally! This is valid for all countries of course.

Nevertheless the French imprint is strong in ESSKA, very often we find a Frenchman or a Frenchwoman in the most prestigious fellowships of ESSKA because these Frenchmen have a great scientific value (ESSKA-AOSSM ESSKA-APKASS). I believe that there was not an ESSKA-AOSSM travelling fellowship which did not pass in Lyon probably for the orthopaedic surgery but perhaps also for the gastronomy with our famous out three stars restaurant "Bocuse"! But here I am a little too Lyonnais and a little too chauvinistic... shhh.

**ME: So why does Lyon have this place in Europe?**

**D.D.:** Because there is a strong history of orthopaedics in Lyon. For the knee of course, written by Albert Trillat, Henri Dejour, Pierre Chambat, Philippe Neyret, and the generations that followed the list is getting too long. For the shoulder with Gilles Walch but also the prosthetic and arthroscopic hip. Pierre Chambat was president of ESSKA in 2000. So you could say that there is a special relationship between Lyon and ESSKA! More seriously, people are attracted to Lyon because we have developed strong ideas there, and the public and private centres work in great coherence and unity and that is unique! Our "Journées Lyonnaises de chirurgie du genou", created in 1971, are the vector of this sacred union and we are still perceived as a school of knee surgery year after year - the Lyon School of Knee Surgery!

**ME: What is your relationship with ESSKA?**

**D.D.:** My link with ESSKA was written in my DNA in 1996 in Budapest for my first oral presentation at this congress. Since then I have always had a role in the symposia, ICL Keynote lectures. I have always

loved this friendly society where I found my unwavering friends like Stefano Zaffagnini. I had the honour of doing the ESSKA-AOSSM travelling fellowship in 2003 with Christian Fink and Fredrik Almquist my godfather being KP Benedeto. It is my heart, it is a little bit my life, I extended to the European level what I had experienced with SFA.

**ME: But how did you become president of ESSKA?**

**D.D.:** Do you want to know how the most beautiful thing in my professional life became reality? It was an incredible adventure, where one day Niek Van Dijk came to interview me during an SFA congress in Bordeaux to see if I could be a candidate for this position. This was an exceptional honour as I was chosen "outside the ESSKA board" which is very rare. In 2016 I was proposed as second vice-president. It was an offer I couldn't refuse. It was not in my "plan career" because I have never done it. I am not a lobbyist nor a careerist, I take what life gives me and I do it 100%.

**ME: What impact does it have to be president of ESSKA?**

**D.D.:** I would say to have the power to "DO" and to achieve, to get out of one's personal problematic and to speak only in the "Name of" by eliminating one's personal affects, to gather the ideas and proposals of all, then to put them in agreement, to be at the centre of a group of high level people (the board) and to fight to obtain a positive and constructive consensus. The role of the president is more attached to the global vision than to an operational role because there is an extremely efficient operational team led by our Executive Director Zhanna Kovalchuk and each member of the board takes on his or her share of operational tasks. It's a permanent joy. You can understand why politicians fight for power, which is exhilarating. But one must always remain simple and

oneself, open-mindedness is a fundamental value.

**ME: What about the impact on your personal and professional life?**

**D.D.:** Yes, this has an impact on the time spent because it takes a lot of real time and also psychological time because you never forget what is going on. It is certain that I have had to withdraw a little from the time I spend with my group of orthopaedic surgeons at Lyon-Ortho-Clinic and from the day-to-day running of the group, but my associates have helped me considerably and our group has never been so strong. Now I believe that the perfect organisation of my secretarial staff and my nurses are there to lighten and make my daily task as an orthopaedic surgeon so much easier. Here too, the strength of the group, of a team focused on a common goal, is the guarantee of success. I have met and worked with incredible teams in ESSKA, both my old office and the new one, with the strong and efficient staff. The intense interactions, the risky and necessary decision making, the exchanges with our friends from all over the world to agree the programmes of our congresses and scientific societies, ISAKOS, AOSSM, APKASS, SLARD, up to the Pope we visited in November 2019 as part of our charity mission "Cycling for Science"... Everything was and is wonderful.

Thank you to all my friends who have been there on a daily basis in this exercise as President of ESSKA which is an UNIMAGINABLE gift. I am a happy man. ■

## ESSKA CONGRESS ISSUE

Michael T. Hirschmann<sup>1,2</sup>, David H. Dejour<sup>3</sup>

<sup>1</sup>Department of Orthopaedic Surgery and Traumatology, Kantonsspital Baselland (Bruderholz, Liestal, Laufen), Bruderholz, Switzerland

<sup>2</sup>University of Basel, Switzerland

<sup>3</sup>Department of Knee surgery and Sportmedecine Lyon-Ortho-Clinic, Lyon - France



David H. Dejour



Michael T. Hirschmann

it should also foster exchange of ideas, networking and discussions through controversial topics. Look into it to be prepared to our “Science Week”.

### “Fashion meets Science” – the 19<sup>th</sup> ESSKA congress theme in Milan

For the first time ESSKA decided to have a theme “When Fashion meets Science” for its biennial congress. What could be better than have the congress in Milan one of the world capitals of fashion?” During this “Science Week” top-class faculty will present their latest “haute couture” on the scientific catwalk... like the so called “Fashion Week”.

What do fashion and science have in common? There are many similarities between the worlds of Fashion and Science.

We all have great interest in brand new and fashionable instruments, techniques, and handy tools. In our daily business we do need a certain amount of creativity and originality and this is definitely what people are looking for when they come to such an event. Congress time is also showtime. However, behind this show the backstage work is highly demanding for marketing, designers and backstage workers. To create and invent new designs, new techniques or new classifications you have to have a broad knowledge, at best based on science and you need to consider the history and failures, not to re-invent the wheel, in particular repeat the mistakes of the past.

You can bring back on stage the famous Trumpet like trousers of the 70’s, but these might come back re-shaped and updated using new technology and showing new design patterns. In orthopaedics, from time to time we do recognize a revival of so-called old-fashioned techniques or implants. However, these only

return in an updated version together with a more selective indication, new material and new surgical methodology. The scientific and development advancements challenge surgeons and scientists to constantly review their armamentarium and skillset.

ESSKA as a scientific society is the warrant of what is delivered to the participants and behind the lightshow the programme committee has done the perfect selection to get the most updated trends in shoulder arthroscopy, ankle arthroscopy, hip arthroscopy, knee arthroscopy, treatment of degenerative joint disease, and of course sports.

This special congress issue of MO Journal focuses on latest developments and innovations in the field of knee surgery, arthroscopy, traumatology and sports medicine. Therefore, some of the landmark papers submitted to ESSKA congress 2020 in Milan were selected and are highlighted in this issue.

In the article by Matthieu Ollivier and colleagues patient specific cutting guides are introduced as helpful tools for intraarticular high tibial osteotomies. Major benefits such as a more sophisticated 3D planning including the option of performing a virtual osteotomy even before surgery are highlighted. In addition, surgical tips and tricks are given and are outlined in detail.

In another landmark article Pablo Gelber emphasizes the benefits of fresh osteochondral allografts as an alternative to metal and plastic for knee osteoarthritis in young patients with old knees. Fresh osteochondral allograft is an effective biologic, durable treatment option for localized femoral, patellar or tibial osteochondral defects. It is performed in a single-stage technique and may be preferable to other surgical alternatives, particularly in

the setting of unshouldered cartilage lesions, extensive subchondral edema, or extensive bone loss that requires restoration. The goal of surgery is restoration of a joint without the need of metallic implants, symptom relief and functional improvement, with the possibility of delaying or eliminating the need for future knee arthroplasty.

In the third article a diagnostic algorithm for acute syndesmotic injuries in upper ankle sprains is presented by Sjoerd Stufkens. He pointed out that no single physical examination test is accurate enough to establish the diagnosis of an isolated syndesmotic injury. A combination of tests such as inability to hop, local syndesmosis ligament tenderness, the external rotation and squeeze stress tests may be useful

Finally, the “functional knee phenotype concept” and its impact on the controversy of proper frontal alignment in TKA are presented and discussed. Breaking long-held dogmas can cause a certain amount of uncertainty, but it can also be seen as an opportunity to rethink alignment and build a scientific foundation for a more patient-specific approach to TKA. In this paper the different alignment concepts for TKA are described and the possible pros and cons are presented. Furthermore, it is presented how the functional “knee phenotype concept” allows a different perspective on knee alignment and how its use could foster an open and evidence-based discussion about a more personalized alignment in TKA.

The ESSKA team is happy to offer you these articles and we are waiting for you for the ESSKA “science week”! ■

### Dear MO journal readers

#### We all have to face a very challenging situation all over Europe and all over the world.

As a nonprofit medical organisation, ESSKA is very concerned about the worldwide crisis, and the countries which are the most impacted by COVID-19.

ESSKA empathize with you and yours and we would like to send you our best wishes for staying and being in good health.

On behalf of the ESSKA leadership and the Scientific team of the ESSKA Congress, we would like to inform you that, due to the continual spread of the Novel Coronavirus (COVID-19) in Europe, the decision was taken to postpone the ESSKA Congress.

This editorial was written before the crisis began. In this difficult time for all of us it should serve as food for thought and positive scientific distraction. As it stands,

## ESSKA @ HOME 2021 "WHEN FASHIONS MEETS SCIENCE"

David H. Dejour

Department of Knee surgery and Sportmedecine Lyon-Ortho-Clinic, Lyon - France

"When fashion meets science" was our slogan for the ESSKA 2020 congress in Milan. The timing was strange because just after the Milan Fashion Week in February 2020, a series of seemingly improbable events began to unfold. We were beginning to realise that holding our May 2020 congress would probably be impossible and we decided to postpone it until September 2020. A massive amount of reorganisation, communication to our members, speakers and industry partners was urgently needed. The orthopaedic world was moving in all directions, and everyone was still considering doing their events. Then the waves followed one another like a tsunami without respite to make us decide to reschedule a second time in May 2021 and finally to transform our magnificent congress into a new and very current form, namely VIRTUAL. So YES, we have ended up becoming very fashionable as all communication and exchanges have become virtual! Every cloud has a silver lining, and we have become warriors

ready to fight by reorganising the troops, mobilising positive energies and seeking new, ever more attractive solutions.

The body of our congress is SCIENCE delivered without bias and like the couriers that have taken over our cities, ESSKA brings the content of what you have ordered to your home. The science programme was once again worked on by our programme chairs Michael Hirschmann, Kristian Samuelsson, Elizaveta Kon and myself to adapt it to the innovative technology we will be using. 131 hours of scientific content!!! More than 450 speakers, 150 top class sessions will be offered to you live and on demand, just like our film broadcasting sites.

How does it work?

It's actually quite simple. After registering online you will have unlimited access for three months to all scientific content and industry sessions.

The congress will take place over four days, from Wednesday 12<sup>th</sup> May until Saturday 15<sup>th</sup> May and will be visible "on demand" 24 hours a day 7 days a week!

What is the general pattern?

The general scheme will be based on the principle of television channels: a live channel with a TV set and four channels each dedicated to an "all about" subject.

The LIVE channel will have moderators who will chat live with the speakers. All the highlight and keynote lectures will be on this channel. The scientific standard will be very high, bringing us all the latest innovations and updates in all areas of ESSKA. It promises to be lively with interaction with the audience through live Q&A. Our speakers have made a considerable effort to give you the best of their science. Tuesday through Friday evening from 6 to 10 pm, and on Saturday morning, this channel will be open and the content can be viewed and reviewed on demand afterwards.

For the other four channels the content will be pre-recorded in the form of ESSKA WEBINAR, i.e. very interactive with a take home message, introductions and moderation by our team. I believe that the general

aspect will be very fluid like a pre-recorded live broadcast.

### TUE. 11<sup>TH</sup> MAY

We start with the young surgeons, interns and students. It is a kind of pre-congress ESSKA and from 4.45 pm to 9 pm FORTE will offer an attractive programme on the knee, shoulder and ankle but also a forum on "the success of the intern" in the start of their career. It is also on Tuesday 11 May that all the free papers will be put online, as well as the E-Posters, which is often the moment for an intern or a young surgeon to "step on the podium" for the first time in a scientific event.

### WED. 12<sup>TH</sup> MAY

We start the congress with a very short inaugural session and then Andy Williams will

**19<sup>th</sup> ESSKA CONGRESS**  
11-15 May 2021  
Fashion Meets Science

+49 (0) 30 246 03 250 | [esska2020@it-group.org](http://esska2020@it-group.org)

CONGRESS+ | PROGRAMME+ | REGISTRATION | INDUSTRY+ | MEDIA & DOWNLOADS

**ESSKA@Home**

450+ EXPERTS / SPEAKERS | 130+ SCIENTIFIC HOURS | 150+ TOP CLASS SESSIONS

REGISTRATION IS OPEN! CME: APPLICATION HAVE BEEN SUBMITTED!

ON DEMAND CONTENT AFTER THE CONGRESS | ALL FROM THE COMFORT OF YOUR OWN HOME!

Join our Live TV channel (opens) | 100 speakers presenting 4 top class keynote programmes over 4 days with the abstract world of the Research's Programme on the 11<sup>th</sup> day | Get your scientific update with the 130+ abstracts and over 450 Posters!

Every day from 6-10 pm AN ESSKA LIVE TV

Channel 1: KNEE | Channel 2: SHOULDER | Channel 3: OTHER CONTENT

Twitter, Facebook, YouTube, LinkedIn icons

## Scientific Programme Overview now online

DAY/ CHANNEL	Channel 1 LIVE	Channel 2 On demand	Channel 3 On demand	Channel 4 On demand	Channel 5 On demand	Channel 6 - Free Papers and E-Posters Accessible during the whole time of the congress				Industry Channel LIVE	
Tuesday 11 May	Industry Symposia 14:00-15:00										
	Industry Symposia 15:00-16:00										
	Industry Symposia 16:00-17:00										
	Resident's Days 16:45-21:00										
	Industry Symposia 21:00-22:00										
Wednesday 12 May	Highlight and Keynote Lectures 18:00-22:00	All about ACL 9:00-18:00	All about Shoulder surgery 9:00-18:00	All about Foot & Ankle 9:00-18:00	All about Hip Arthroscopy 9:00-18:00	Free Papers ACL	Free Papers Cartilage & Meniscus	Free Papers Degenerative Knee (I)	Free Papers Shoulder, Elbow and Sports	Free Papers Hip and Ankle	Programme provided by Industry Partners 9:30-17:00
Thursday 13 May	Industry Symposia 17:00-18:00	All About Meniscus 9:00-18:00	All about Rotator Cuff Repair 9:00-18:00	Hip Arthroscopy and Ortho- biologics 9:00-18:00	All about Sports 9:00-18:00						Programme provided by Industry Partners 9:30-17:00
	Highlight and Keynote Lectures 18:00-22:00										All about Complex Knee instability 9:00-18:00
Friday 14 May	Industry Symposia 17:00-18:00	Partner Societies 9:30-13:00	All about Degenerative Knee (III) 9:30-13:00	All about Patellofemoral Instability 9:30-13:00							
	Highlight and Keynote Lectures 18:00-22:00										Industry Symposia 8:30-9:30
Saturday 15 May											

give the new lecture that we are inaugurating this year: The Werner Müller Lecture called "The MCL- the Forgotten Ligament. How anatomic form and function optimise practice - The Werner Müller Principle". Together with the Ejnar Erickson Lecture, these are now the two main presentations of our congress. Then it will be the turn of the cycle of highlight and keynote lectures.

Each of the other channels will cover a specific topic: All about ACL, All about shoulder surgery, All about ankle surgery and All about hip arthroscopy.

### THUR. 13<sup>TH</sup> MAY

The LIVE channel will continue with our highlight and keynote speakers. Our other channels will cover: All about meniscus, all about rotator cuff tear, all about hip arthroscopy and orthobiologic, all about sports.

### FRI. 14<sup>TH</sup> MAY

The LIVE channel will continue with our highlight and keynote speakers.

Our other channels will cover: All about complex knee instability, All about degenerative knee, All About cartilage, All about shoulder and elbow.

### SAT. 15<sup>TH</sup> MAY

This will be the last day. The session will be morning only, from 9:30 to 12:30, and we will finish on the LIVE channel with the Ejnar Eriksson reading done by Matteo Denti: ACL reconstruction from the past to present - What have I learned from Ejnar? Then the section sessions end on a high note with Women in ESSKA!!!

Our dedicated channels will link to the world and our

partner societies ISAKOS, AOSSM APKASS, SLARD, the degenerative knee, and the patello femoral session!

This is a description of our great event that we already know will be successful because of the large number of registrations and the great participation of the industry, which have followed and supported us in an incredible way.

We will be on top of our game and you will be surprised by the strength of this new "formula 1" of the virtual congress!

Visit our website, register, and don't forget to tell those around you about ESSKA, because it is thanks to you that it will be a success! Make groups to watch and participate together at home or in your hospital. Take selfies, send us those moments of sharing, go on social networks to talk about it, it all helps!

I would like to say thank you to all our highlight and keynote speakers who all attended, to all

our ICL chairs and symposia, to all our young participants who will be presenting, to the authors of the e-posters and to all the exceptional organising committees who made this outstanding congress possible. THANK YOU to all of you who will make this congress UNBELIEVABLE as a building block in the history of ESSKA!

You'll love it and you'll have three months to watch, rewatch and replay all the sessions of ESSKA VIRTUAL 2021!

We look forward to seeing you.

## FRESH OSTEOCHONDRAL ALLOGRAFT (FOCA) TRANSPLANTATION OF THE KNEE A RARE USED TECHNIQUE IN EUROPE WITH LONG TERM GOOD RESULTS

Pablo E. Gelber<sup>1,2</sup>

1-Department of Orthopaedic Surgery. Hospital de la Santa Creu i Sant Pau.  
Universitat Autònoma de Barcelona. Barcelona, Spain

2-ICATME-Hospital Universitari Dexeus - Universitat Autònoma de Barcelona.  
Sabino Arana, 5-19. 08028. Barcelona, Spain  
[personal@drgelber.com](mailto:personal@drgelber.com)

### INTRODUCTION

Injuries in the articular cartilage of the knee are frequent in young and active people [1]. It is a common finding during knee arthroscopic surgery, with a reported prevalence of up to two third of the cases. Regarding only localized cartilage defects, they can be seen in around 20% of patients [2]. In these young group of people, knee arthroplasties show low satisfaction rates and high failure rates due to accelerated loosening or wear [3, 4].

Multiple surgical options have been developed for localized articular cartilage defects, including autologous chondrocyte implantation, subchondral marrow stimulation, osteochondral autograft transplantation, and fresh osteochondral allograft (FOCA) transplantation. FOCA is an effective biologic, durable treatment option for localized femoral, patellar or tibial osteochondral defects [5]. It is performed in a single-stage technique and may be preferable to other surgical alternatives, particularly in the setting of unshouldered lesions, extensive subchondral edema, or extensive bone loss that requires restoration.

One of the main advantages of using FOCAs is the presence of metabolically active chondrocytes without concurrent donor

site morbidity [6]. Most soft tissue and bone allografts can be easily storage in tissue banks for long periods of time under cooling techniques. For the cartilage tissue cooling eliminates the cell viability, which is crucial for the success of transplantation. Fresh storage of the osteochondral allograft, on the other hand, preserve this cell viability. However, this presents critical limitations from a logistic point of view. Due to this limitations and other reasons, FOCA other than in USA is scarcely available worldwide. While efforts are being done in some countries to provide FOCA to surgeons, it is still only available in Spain and few others places in Europe. This review provides an overview of the indications, different techniques and outcomes of FOCA that has been performed in USA for more than 40 years now, but is surprisingly still in its babyhood around Europe and other areas of the world.

### WHEN AND WHY

#### Indications

The goal of surgery is restoration of a joint without the need of metallic implants, symptom relief and functional improvement, with the possibility of delaying or eli-

minating the need for future knee arthroplasty. Because this procedure is versatile, indications for FOCA transplantation have been expanded to include complex biologic restoration of the knee joint [7-9].

Currently, FOCA is the only available biologic option for salvage procedures following failed cell-based repair (e.g. autologous chondrocyte implantation), prior osteochondral transplantation for large chondral or osteochondral defects, or failed fixation of large, deep osteochondritis dissecans (OCD) or other osteochondral lesions [10]. Table 1

summarizes the possible indications for FOCA.

The FOCA procedure is highly demanding with regards to logistic, surgical technique and costs. Once transplanted, the FOCA needs a perfect condition and environment to successfully be incorporated to the host recipient to play its protective role for the knee joint. In this sense, there are some conditions that make patients to be excluded without exception (Table 2).

#### Storage techniques and basic science

- Patients between 15 and 50 years of age, who are not candidates otherwise for arthroplasty surgery.
- Localized grade III and IV chondral lesions. Kissing lesions can also be included.
- Chondral or osteochondral lesions larger than 2 cm<sup>2</sup> regardless of whether they are contained or not contained.
- Stage IV osteochondritis dissecans (OCD) or failed previous OCD fixation.
- Spontaneous osteonecrosis of the knee.
- Large posttraumatic osteochondral injuries
- Revision after failed chondral repair surgeries.

Table 1: Indications for FOCA

- BMI > 30 kg/m<sup>2</sup>.
- Large degenerative lesions comprising all three knee compartments.
- Systemic inflammatory diseases, presence of infection or history of osteomyelitis in the graft recipient area and active neoplasia.
- Medical conditions that could affect the incorporation of the graft such as insulin dependent diabetes or smoking. Regarding smokers, they must stop smoking at least 1 months before surgery and for 6 months after the procedure to decrease the risk of infection and non-union [11].

Table 2. Contraindications for FOCA



IMPROVE THE CHANCES

# REDUCE RISK FOR INFECTION

**COPAL<sup>®</sup>G+C**

Reduction of infection risk\* using dual antibiotic-loaded bone cement in high risk patients

- ↓ **34%** in primary hip & knee arthroplasty
- ↓ **69%** in fractured neck of femur
- ↓ **57%** in aseptic revision TKA

\* as reported in study results

The two more common methods for storing allografts are fresh frozen and cryopreservation. With fresh frozen produces the loss of cellular life fails to preserve the chondral tissue [12]. Cryopreservation has also not been proven effective in maintaining cell viability in chondral tissue [13]. A third method of storage is the fresh osteochondral allograft preservation. In this technique, the graft must be harvested within 24hs from death and stored at 4°C. The graft must be transplanted within the first 2 to 4 weeks since harvesting, depending on the method of processing. In addition, the quality and microbiological controls take an extra week. This makes the margin available for surgery to be between 1 and 3 weeks. Currently, some tissue banks have validated an alternative method of storage at 37°C to keep the FOCA viable for up to 2 months [14, 15]. The use of this technique has also some further limitations from a logistic point of view. Obtaining the appropriate graft, both in morphology and cartilage quality, is one of the major limitations of this surgical technique

FOCA transplantation can replace damaged articular cartilage and subchondral bone with mature hyaline cartilage with viable chondrocytes. This technique allows to cover virtually all types of defects, restore complex surfaces and non-contained defects [16-25]. Likewise, it does not cause donor site morbidity as in autologous transplantation, while FOCA causes a minimal immune response in the recipient without clinical relevance [26]. From the immunological point of view, it is not clear if there is an immune response that might put the graft viability at risk. In any case, there have been no report of rank immune rejection of a FOCA of the knee. Regarding the bone component, being a non-vascularized graft, osteocytes of the allograft bone component do not survive, but the bone tissue remains structurally intact and

is mechanically resistant. Over time, the host bone will be replaced by the creeping substitution process [27].

## HOW TO DO IT

### Technical aspects

To prevent graft failure, concomitant pathology that involves the joint must be addressed during graft transplantation or with a staged procedure. As in other chondral repair procedures, axial and coronal malalignment, meniscal tissue loss or ligament instability must be carefully assessed. These factors must be evaluated and treated appropriately. In the same procedure, FOCA transplantation can be performed with a ligamentous reconstruction, meniscal transplant and/or corrective osteotomies [28].

Alignment is critical, and corrective osteotomies must be performed even in small malalignments as little as 2 degrees [29]. They can be ideally performed concomitantly in the same surgical procedure. Alternatively, the osteotomy can be done in a first stage, and the FOCA can be performed after 3 or 4 months.

There are two ways of transplanting FOCA into the host area:

#### • Dowel or Plug technique

is recommended for isolated, well-defined and easily accessible defects (Figure 1). Eventually, when the defect is asymmetric, the “Snowman or Mastercard” technique using two transplants overlapping each other can be performed (Figure 2). However, a higher revision rate has been reported with this later technique [30].

The dowel technique involves the following general surgical steps (Figure 3):

a) Recipient area:

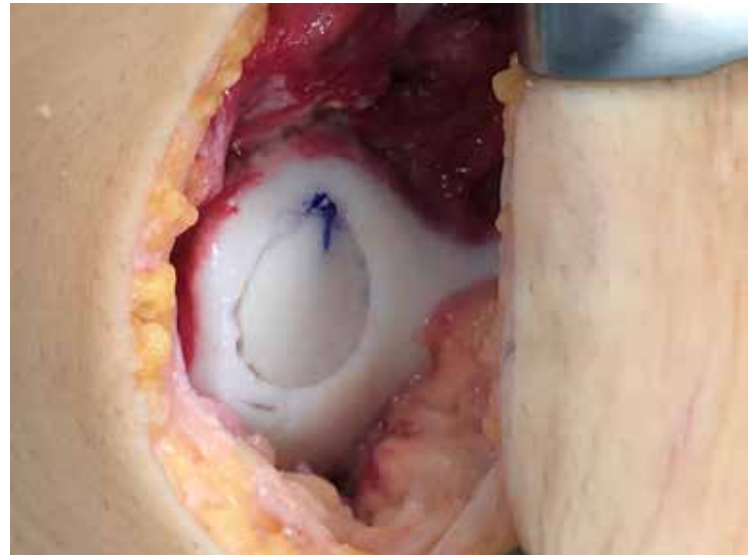


Figure 1: Right knee - Dowel technique  
In this case, one 24mm-diameter FOCA plug was transplanted in the lateral aspect of the trochlea.

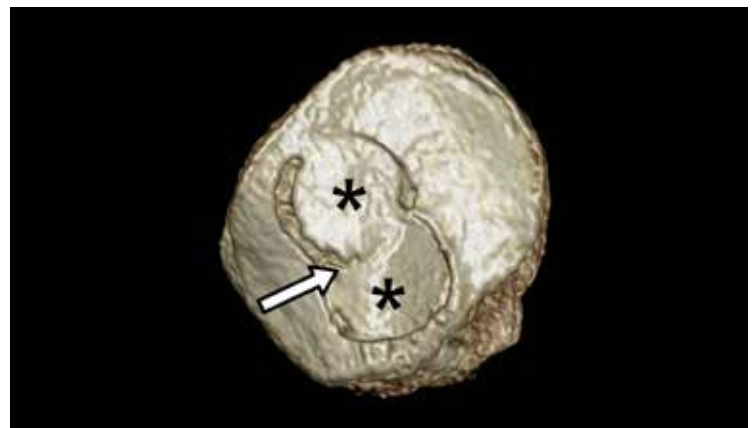


Figure 2: 3D TC scan of a right patella – “Snowman or Mastercard” technique  
In certain asymmetric osteochondral injuries, two plugs (\*) are partially supra-adjacent to each other (arrow) as a valuable option.

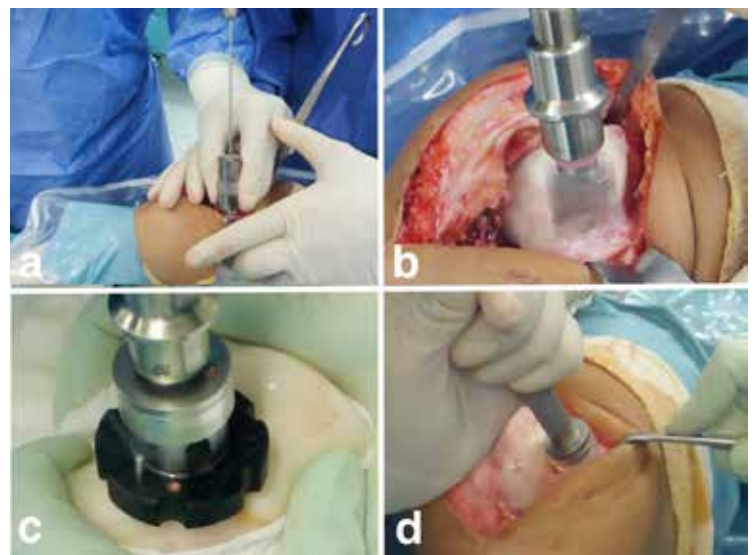


Figure 3: Dowel FOCA technique  
(A) Shows the selection of the appropriate sizing guide with the central pin  
(B) reaming the recipient area with a flat drill bit with the selected diameter  
(C) the graft is then prepared with its corresponding coring reamer matching the prepared defect  
(D) Pressfit reduction of the osteochondral plug is accomplished using thumb pressure or light tap until the surface is flush with the surrounding cartilage.

The appropriate sizing guide is chosen and placed on the injured zone and the drilling pin is inserted. A cannulated flat drill bit is used to prepared the cylindrical defect with the selected diameter (Figure 3a,b)

## b) Graft preparation:

A coring reamer with the same diameter as used for the recipient area preparation is used to obtain the osteochondral bone plug (Figure 3c)

## c) Graft placement:

The plug is introduced first with thumb pressure obtaining a pressfit fixation. A light tap can be used to fully insert the graft until it is flush with the surrounding cartilage (Figure 3d).

## • Shell or Resurfacing technique

is recommended for large or multiple lesions in which a dowel technique is not suitable to cover the entire defect (Figure 4). This technique involves a recipient area and graft preparations that have to be tailored according to the specific location and size of the defect.

In all cases, it is mandatory to remove the bone marrow from the subchondral bone of the allograft as much as possible to decrease any risk of immune rejection. This is accomplished with high pressure pulsatile irrigation with at least 6 liters of normal saline. This step is performed on the bone side of each allograft before implantation in the recipient area.

## PATELLOFEMORAL TRANSPLANTATIONS

When a FOCA in the patellofemoral compartment is planned, maltracking should be ruled out, since it may be the underlying cause of early allograft

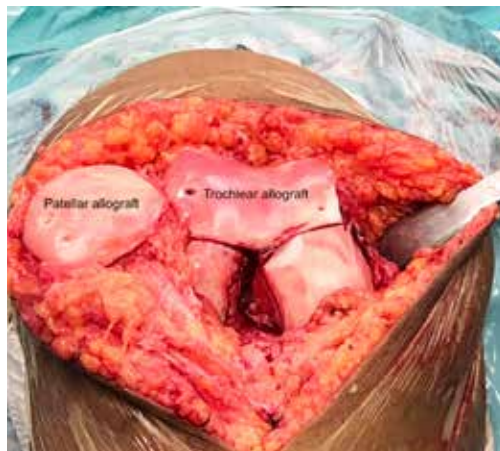


Figure 4: Right knee - Complete FOCA resurfacing of the patellofemoral joint using the shell technique is indicated when invalidating knee pain is due to severe large bipolar defects of both joint surfaces.

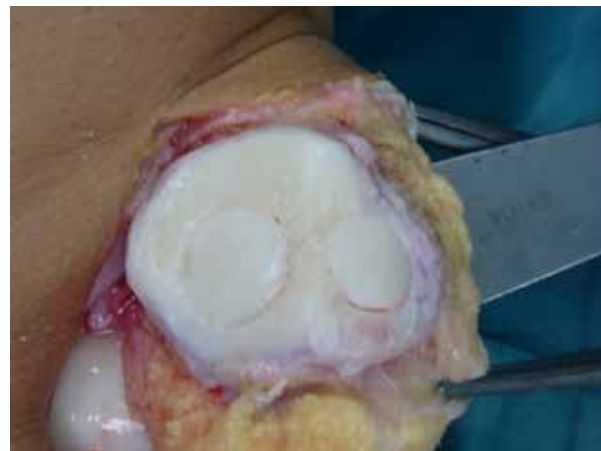

Figure 5: Left patella - plug technique. The plug technique is used whenever possible and is also the preferred technique used in the patella.

failure. In these cases, FOCA should be combined with soft tissue techniques such as lateral retinal release or lengthening and reconstruction of the medial patellofemoral ligament. Tibial tuberosity transfers are also indicated to correct abnormal patellar height and/or anteromedialization in case of TT-TG distance greater than 15mm [32]. It has been reported that up to 40% of FOCA for the patellofemoral joint are combined with additional surgeries to improve patella tracking [39].

For the patellofemoral joint the plug technique is always preferred (Figure 5). However, in large patellofemoral injuries involving 2/3 of the patella, broad lesions of a dysplastic trochlea or in locations of difficult access, the shell technique is mandatory. The shell technique for the patella is identical to that used in prosthetic surgery when a patellar implant is used for replacement. After measuring the patellar surface and thickness, a parallel osteotomy is made using a patellar guide from a knee replacement instrument set. To minimize the risk of fracture, a residual thickness between 12 and 15 mm should be maintained [8]. Similarly, parapatellar denervation is performed with electrocautery to reduce the risk of anterior knee pain [40].

Bipolar chondral lesions of the patella and trochlea may be considered a relative contraindication due to the limited success of clinical outcomes and the considerable percentage of failures [37]. This is particularly true when they are compared with isolated Dowell technique transplantation performed in the femoral condyles [38]. The direct relationship between allograft size and graft failure has also been demonstrated for the patellofemoral joint [33]. Then, FOCA procedure in large bipolar patellofemoral injuries have to be done only when an invalidating knee pain makes no other choice reasonable (Figure 4 and 6) [7].

Chondral or osteochondral defects in the patellofemoral joint have shown less favourable outcomes compared to other areas of the knee. Pain from the patellofemoral joint is usually multifactorial, and this make the decision-making process more challenging [31]. There are only case series reporting on the use of large FOCA of the patellofemoral joint [32-35]. However, this is a common finding for any chondral procedure of the patellofemoral joint. In this sense, recent studies have shown very consistent long-term results of FOCA, which are comparable or even better to other chondral repair procedures. Gracitelli

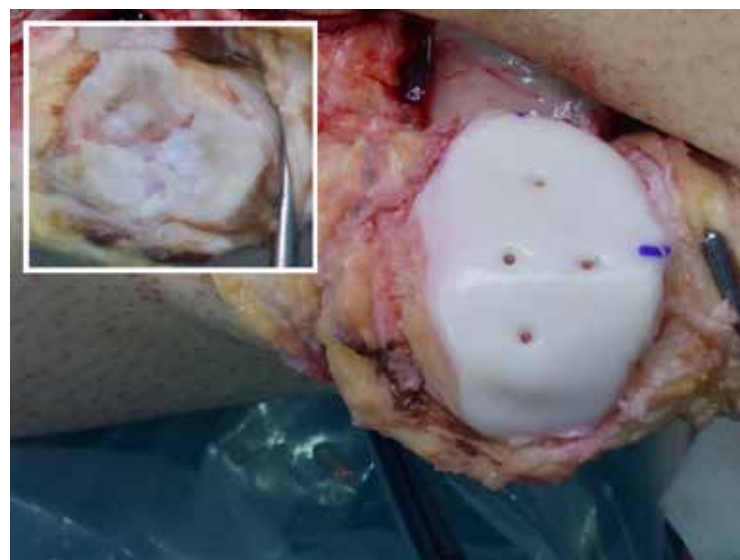


Figure 6: Right knee - patella with shell technique. In large defects, more frequently in the patella (upper left), the shell technique is preferably performed.

et al. [32] reported a survival rate of 78.1% at 10 years and 55.8% at 15 years. For isolated trochlear defects, Cameron et al. [36] showed even higher survival rate of 100% at 5 years and 91.7% at 10 years. These results should encourage the use of FOCA for the patellofemoral joint also.

## TIBIOFEMORAL TRANSPLANTATIONS

Similarly, to other areas of the knee, the plug technique should be chosen whenever possible. Conversely, in cases of large and uncontained femoral condyle injuries, the shell technique has to be performed (Figure 7). As commented before, alignment is a key factor for a favourable outcome and survival rate of the transplanted allograft [29].

Although no randomized controlled trials have been reported with the use of FOCA transplantation, several studies have reported short, mid and long term follow up data. Most of them have reported outcomes in the femoral condyles. For this indication FOCA shows high survival rates with good functional results. In fact, patients are expected to restore their pre-injury activity in up to 80% of the cases [41-43].

One of the largest series reported 129 cases of FOCA procedures in the femoral condyles, showing a survival of 82% at 10 years, 74% at 15 years and 66% at 20 years [23]. Factors leading to graft failure included low activity patients, age older than 30 years, BMI > 35 and knees with 2 or more previous surgeries [44]. Regarding the series with longest follow-up with mean 21.8 years, a survival of 91% at 10 years, 84% at 15 years, 69% at 20 years and an estimated 59% at 25 was reported [45]. This series included highly active patients only which were younger than 40 years old.

Some studies have been published regarding FOCA to replace large osteochondral lesions of the tibial plateau, a more infrequent condition that also required a more demanding surgical technique [9].

The dowel technique for tibia plateau involves following general surgical steps (Figure 8):

### a) Bed preparation

A vertical bone cut is performed in the center of the corresponding tibial spine. The horizontal osteotomy is performed with a minimum cut to obtain a flat surface with healthy bleeding cancellous bone (Figure 8a)

### b) Graft preparation

It is performed according to the dimensions previously measured in the recipient area. This will be a delicate step and it is always advisable to calculate for some oversizing. This oversizing can be corrected during the graft placement. (Figure 8) Finally the graft is placed in the defect and visually observed and checked under fluoroscopic control

### c) Graft fixation

Ideally achieved with 2 headless titanium compression screws with a variable threaded pitch (Acutrak Standard, Acumed, Oregon), which provides strong compression. Alternatively, 4mm cancellous screws can be used (Figure 8d).

In most of the cases, the FOCA procedures were performed after tibial plateau fractures with posttraumatic chondral lesions. Shasha et al. [46], with a mean follow-up of 12 years, obtained a survival rate of 80% at 10 years and 65% at 15 years. Comparable results were observed in the Gross et al. study [22] but one third of the patients needed total knee arthroplasties after 10 years from the index procedure.

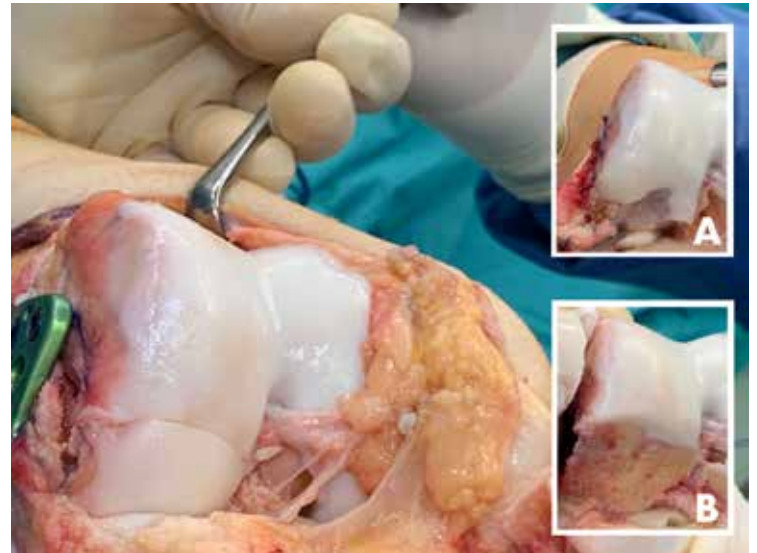


Figure 7: Right knee - large defect of condyle (A) Case with large uncontained defect of femoral condyle, (B) host preparation to receive the allograft and finally a large FOCA in shell technique in place (large picture).

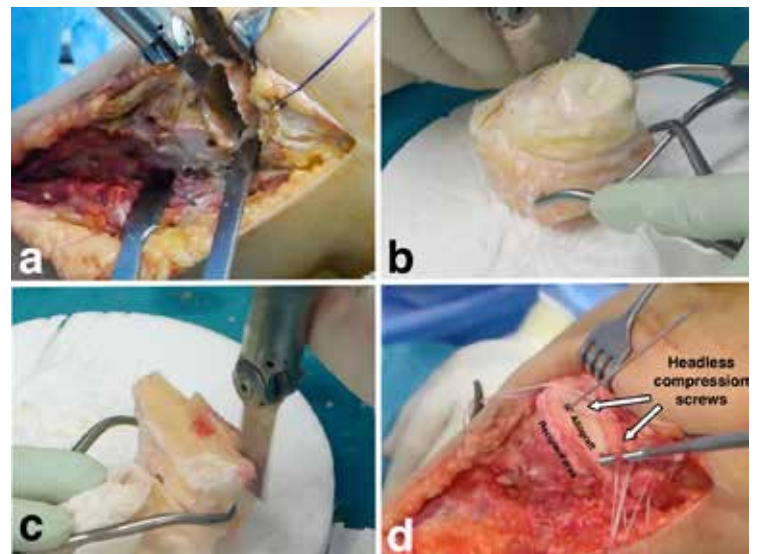


Figure 8. Left knee - lateral tibial plateau transplantation (A) shows the horizontal cut of the tibia plateau with a minimum cut to obtain a flat, bleeding bone from the injured tibial plateau; (B & C) Graft preparation done accordingly to the prepared and trimmed defect; (D) Fixation of the osteochondral graft with two titanium headless compression screws (Acutrak Standard, Acumed).

## CONCLUSION

FOCA transplantation is a useful procedure for large osteochondral defects of the knee in young and active patients to delay artificial prosthetic joint replacement. Proper patient selection, accepting contraindications as well as evaluation

and reducing risk factors for early failures (malalignment, ligamentous insufficiency and meniscal tissue loss) are essential to ensure graft survival and good clinical outcomes. FOCA for femoral defects have excellent results at medium and long term follow up. Slightly worse outcomes can be expected for the patellofemoral joint, and more specifically for bipolar osteochondral injuries.

## Bibliographie

1. FLANIGAN DC, HARRIS JD, TRINH TQ, SISTON RA, BROPHY RH. PREVALENCE OF CHONDRAL DEFECTS IN ATHLETES' KNEES: A SYSTEMATIC REVIEW. *MED SCI SPORTS EXERC.* 2010;42:1795-801.
2. AROEN A, LOKEN S, HEIR S, ET AL. ARTICULAR CARTILAGE LESIONS IN 993 CONSECUTIVE KNEE ARTHROSCOPIES. *AM J SPORTS MED.* 2004;32(1):211-215.
3. LONNER JH, HERSHMAN S, MONT M, LOTKE PA. TOTAL KNEE ARTHROPLASTY IN PATIENTS 40 YEARS OF AGE AND YOUNGER WITH OSTEOARTHRITIS. *CLIN ORTHOP RELAT RES.* 2000;380:85-90.
4. BAYLISS LE, CULLIFORD D, MONK AP, GLYN-JONES S, PRIETO-ALHAMBRA D, JUDGE A, COOPER C, CARR AJ, ARDEN NK, BEARD DJ, PRICE AJ. THE EFFECT OF PATIENT AGE AT INTERVENTION ON RISK OF IMPLANT REVISION AFTER TOTAL REPLACEMENT OF THE HIP OR KNEE: A POPULATION-BASED COHORT STUDY. *LANCET.* 2017;389:1424-30.
5. FILIPPO F, CINQUE M, CHAHLA J, GODIN JA ET AL CLINICAL OUTCOMES AND FAILURE RATES OF OSTEOCHONDRAL ALLOGRAFT TRANSPLANTATION IN THE KNEE A SYSTEMATIC REVIEW. *AM J SPORTS MED.* 2018 DEC;46(14):3541-3549
6. PEARSALL AW, TUCKER JA, HESTER RB, HEITMAN RJ. CHONDROCYTE VIABILITY IN REFRIGERATED OSTEOCHONDRAL ALLOGRAFTS USED FOR TRANSPLANTATION WITHIN THE KNEE. *AM J SPORTS MED.* 2004;32(1):125-131
7. GELBER PE, RAMÍREZ E, GRAU A, FARIÑAS O, MONLLAU JC. FRESH OSTEOCHONDRAL RESURFACING OF THE PATELLOFEMORAL JOINT. *ARTHROSC TECH* 2019 [EPUB AHEAD OF PRINT].
8. GELBER PE, PERELLI S, IBAÑEZ M, RAMÍREZ E, FARIÑAS O, MONLLAU JC, SANCHIS V. FRESH OSTEOCHONDRAL PATELLAR ALLOGRAFT RESURFACING. *ARTHROSC TECH* 2018;7:e617-e622.
9. GELBER PE, ERQUICIA J, RAMÍREZ E, FARIÑAS O, MONLLAU JC. FRESH OSTEOCHONDRAL AND MENISCUS ALLOGRAFTING FOR POSTTRAUMATIC TIBIAL PLATEAU DEFECTS. *ARTHROSC TECH* 2018;7:e661-e667
10. PERELLI S, MOLINA-ROMOLO A, COSTA-PAZ M, ERQUICIA JI, GELBER PE, MONLLAU JC. INTERNAL FIXATION OF OSTEOCHONDRITIS DISSECANS OF THE KNEE LEADS TO GOOD LONG-TERM OUTCOMES AND HIGH DEGREE OF HEALING WITHOUT DIFFERENCES BETWEEN FIXATION DEVICES. *J CLIN MED* 2019 Nov 10;8(11). pii:1934
11. PEARSON RG, CLEMENT RG, EDWARDS KL, SCAMMELL BE DO SMOKERS HAVE GREATER RISK OF DELAYED AND NON-UNION AFTER FRACTURE, OSTEOTOMY AND ARTHRODESIS? A SYSTEMATIC REVIEW WITH META-ANALYSIS. *BMJ OPEN.* (2016) NOV 14;6(11):e010303
12. GELBER PE, GONZÁLEZ G, LLORETA JL, REINA F, CÁCERES E, MONLLAU JC. FREEZING CAUSES CHANGES IN THE MENISCUS COLLAGEN NET. A NEW ULTRASTRUCTURAL MENISCAL DISARRAY SCALE. *KNEE SURG SPORTS TRAUMATOL ARTHROSC.* 2008 16:353-359.
13. GELBER PE, TORRES R, GONZÁLEZ G, GARCÍA GIRALT N, CÁCERES E, MONLLAU JC. CRYOPRESERVATION DOES NOT ALTER THE ULTRASTRUCTURE OF THE MENISCUS. *KNEE SURG SPORTS TRAUMATOL ARTHROSC.* 2009;17:639-644.
14. PALLANTE AL, BAE WC, CHEN AC, GÖRTZ S, BUGBEE WD, SAH RL. CHONDROCYTE VIABILITY IS HIGHER AFTER PROLONGED STORAGE AT 37 DEGREES C THAN AT 4 DEGREES C FOR OSTEOCHONDRAL GRAFTS. *AM J SPORTS MED.* 2009;37(SUPPL 1):24S-32S.
15. GARRITY JT, STOKER AM, SIMS HJ, COOK JL. IMPROVED OSTEOCHONDRAL ALLOGRAFT PRESERVATION USING SERUM-FREE MEDIA AT BODY TEMPERATURE. *AM J SPORTS MED.* 2012;40:2542-8.
16. ASSENMACHER AT, PAREEK A, REARDON PJ, MACALENA JA, STUART MJ, KRYCH AJ. LONG-TERM OUTCOMES AFTER OSTEOCHONDRAL ALLOGRAFT: A SYSTEMATIC REVIEW AT LONG-TERM FOLLOW-UP OF 12.3 YEARS. *ARTHROSCOPY.* 2016;32:2160-8.
17. CAPECI CM, TURCHIANO M, STRAUSS EJ, YOUNG T. OSTEOCHONDRAL ALLOGRAFTS: APPLICATIONS IN TREATING ARTICULAR CARTILAGE DEFECTS IN THE KNEE. *BULL HOSP JT DIS.* 2013;71:60-7.
18. CHAHAL J, GROSS AE, GROSS C, MALL N, DWYER T, CHAHAL A, WHELAN DB, COLE BJ. OUTCOMES OF OSTEOCHONDRAL ALLOGRAFT TRANSPLANTATION IN THE KNEE. *ARTHROSCOPY.* 2013;29:575-88.
19. CHUI K, JEYS L, SNOW M. KNEE SALVAGE PROCEDURES: THE INDICATIONS, TECHNIQUES AND OUTCOMES OF LARGE OSTEOCHONDRAL ALLOGRAFTS. *WORLD J ORTHOP.* 2015;6:340-50.
20. DE CARO F, BISICCHIA S, AMENDOLA A, DING L. LARGE FRESH OSTEOCHONDRAL ALLOGRAFTS OF THE KNEE: A SYSTEMATIC CLINICAL AND BASIC SCIENCE REVIEW OF THE LITERATURE. *ARTHROSCOPY.* 2015;31:757-65.
21. GÖRTZ S, DE YOUNG AJ, BUGBEE WD. FRESH OSTEOCHONDRAL ALLOGRAFTING FOR STEROID-ASSOCIATED OSTONECROSIS OF THE FEMORAL CONDYLES. *CLIN ORTHOP RELAT RES.* 2010;468:1269-78.
22. GROSS AE, SHASHA N, AUBIN P. LONG-TERM FOLLOWUP OF THE USE OF FRESH OSTEOCHONDRAL ALLOGRAFTS FOR POSTTRAUMATIC KNEE DEFECTS. *CLIN ORTHOP RELAT RES.* 2005;435:79-87.
23. LEVY YD, GÖRTZ S, PULIDO PA, MCCAULEY JC, BUGBEE WD. DO FRESH OSTEOCHONDRAL ALLOGRAFTS SUCCESSFULLY TREAT FEMORAL CONDYLE LESIONS? *CLIN ORTHOP RELAT RES.* 2013;471:231-7.
24. MCCULLOCH PC, KANG RW, SOBHY MH, HAYDEN JK, COLE BJ. PROSPECTIVE EVALUATION OF PROLONGED FRESH OSTEOCHONDRAL ALLOGRAFT TRANSPLANTATION OF THE FEMORAL CONDYLE: MINIMUM 2-YEAR FOLLOWUP. *AM J SPORTS MED.* 2007;35:411-20.
25. SHERMAN SL, GARRITY J, BAUER K, COOK J, STANNARD J, BUGBEE W. FRESH OSTEOCHONDRAL ALLOGRAFT TRANSPLANTATION FOR THE KNEE: CURRENT CONCEPTS. *J AM ACAD ORTHOP SURG.* 2014;22:121-33.
26. HUNT HE, SADR K, DEYOUNG AJ, GORTZ S, BUGBEE WD. THE ROLE OF IMMUNOLOGIC RESPONSE IN FRESH OSTEOCHONDRAL ALLOGRAFTING OF THE KNEE. *AM J SPORTS MED.* 2014;42:886-91.
27. OAKESHOTT RD, FARINE I, PRITZKER KP, LANGER F, GROSS AE. A CLINICAL AND HISTOLOGIC ANALYSIS OF FAILED FRESH OSTEOCHONDRAL ALLOGRAFTS. *CLIN ORTHOP REL RES.* 1988;233:283-94.
28. ALFORD JW, COLE BJ. CARTILAGE RESTORATION, PART I: BASIC SCIENCE, HISTORICAL PERSPECTIVE, PATIENT EVALUATION, AND TREATMENT OPTIONS. *AM J SPORTS MED.* 2005;33:295-306.
29. OSTEOCHONDRAL ALLOGRAFT TRANSPLANTATION AND OPENING WEDGE TIBIAL OSTEOTOMY: CLINICAL RESULTS OF A COMBINED SINGLE PROCEDURE. Hsu AC, TIRICO LEP, LIN AG, PULIDO PA, BUGBEE WD. *CARTILAGE* 2017 1-7.
30. FAMILIARI F, CINQUE ME, CHAHLA J, GODIN JA, OLESEN ML, MOATSHE G, LAPRADE RF. CLINICAL OUTCOMES AND FAILURE RATES OF OSTEOCHONDRAL ALLOGRAFT TRANSPLANTATION IN THE KNEE: A SYSTEMATIC REVIEW. *AM J SPORTS MED.* 2018;46:3541-9.
31. NOYES FR, BARBER-WESTIN SD. ADVANCED PATELLOFEMORAL CARTILAGE LESIONS IN PATIENTS YOUNGER THAN 50 YEARS OF AGE: IS THERE AN IDEAL OPERATIVE OPTION? *ARTHROSCOPY.* 2013;29:1423-36.
32. GRACITELLI GC, MERIC G, PULIDO PA, GÖRTZ S, DE YOUNG AJ, BUGBEE WD. FRESH OSTEOCHONDRAL ALLOGRAFT TRANSPLANTATION FOR ISOLATED PATELLAR CARTILAGE INJURY. *AM J SPORTS MED.* 2015;43:879-84.
33. CHU CR, CONVERY FR, AKESON WH, MEYERS M, AMIEL D. ARTICULAR CARTILAGE TRANSPLANTATION: CLINICAL RESULTS IN THE KNEE. *CLIN ORTHOP RELAT RES.* 1999;360:159-68.
34. JAMALI AA, EMMERSON BC, CHUNG C, CONVERY FR, BUGBEE WD. FRESH OSTEOCHONDRAL ALLOGRAFTS: RESULTS IN THE PATELLOFEMORAL JOINT. *CLIN ORTHOP RELAT RES.* 2005;437:176-85.
35. TORGA SPARK R, TEITGE RA. FRESH OSTEOCHONDRAL ALLOGRAFTS FOR PATELLOFEMORAL ARTHRITIS: LONG-TERM FOLLOWUP. *CLIN ORTHOP RELAT RES.* 2006;444:193-200.
36. CAMERON JI, PULIDO PA, MCCAULEY JC, BUGBEE WD. OSTEOCHONDRAL ALLOGRAFT TRANSPLANTATION OF THE FEMORAL TROCHLEA. *AM J SPORTS MED* 2016;44:633-8.
37. MERIC G, GRACITELLI GC, GÖRTZ S, DE YOUNG AJ, BUGBEE WD. FRESH OSTEOCHONDRAL ALLOGRAFT TRANSPLANTATION FOR BIPOLAR RECIPROCAL OSTEOCHONDRAL LESIONS OF THE KNEE. *AM J SPORTS MED* 2015;43:709-714
38. BUGBEE WD: FRESH OSTEOCHONDRAL ALLOGRAFTS. *J KNEE SURG.* 2002 SUMMER;15(3):191-195.
39. OSTEOCHONDRAL ALLOGRAFT TRANSPLANTATION IN THE PATELLOFEMORAL JOINT. A SYSTEMATIC REVIEW. CHAHLA J, SWEET MC, OKOROHA KR. *AM J SPORT MED* 2019 OCT;47(12):3009-3018
40. FAN L, GE Z, ZHANG C, LI J, YU Z, DANG X, WANG K. CIRCUMFERENTIAL ELECTROCAUTERY OF THE PATELLA IN PRIMARY TOTAL KNEE REPLACEMENT WITHOUT PATELLAR REPLACEMENT: A META-ANALYSIS AND SYSTEMATIC REVIEW. *SCI REP.* 2015 MAR 24;5:9393
41. KRYCH AJ, PAREEK A, KING AH, JOHNSON NR, STUART MJ, WILLIAMS RJ III. RETURN TO SPORT AFTER THE SURGICAL MANAGEMENT OF ARTICULAR CARTILAGE LESIONS IN THE KNEE: A META-ANALYSIS. *KNEE SURG SPORTS TRAUMATOL ARTHROSC.* 2017;25:3186-96.
42. NIELSEN ES, MCCAULEY JC, PULIDO PA, BUGBEE WD. RETURN TO SPORT AND RECREATIONAL ACTIVITY AFTER OSTEOCHONDRAL ALLOGRAFT TRANSPLANTATION IN THE KNEE. *AM J SPORTS MED.* 2017;45:1608-14.
43. MCCARTHY MA, MEYER MA, WEBER AE, LEVY DM, TILTON AK, YANKE AB, COLE BJ. CAN COMPETITIVE ATHLETES RETURN TO HIGH-LEVEL PLAY AFTER OSTEOCHONDRAL ALLOGRAFT TRANSPLANTATION OF THE KNEE? *ARTHROSCOPY.* 2017;33:1712-7.
44. NUELLE CW, NUELLE JA, COOK JL, STANNARD JP. PATIENT FACTORS, DONOR AGE, AND GRAFT STORAGE DURATION AFFECT OSTEOCHONDRAL ALLOGRAFT OUTCOMES IN KNEES WITH OR WITHOUT COMORBIDITIES. *J KNEE SURG.* 2017 FEB;30(2):179-184
45. RAZ G, SAFIR OA, BACKSTEIN DJ, LEE PT, GROSS AE. DISTAL FEMORAL FRESH OSTEOCHONDRAL ALLOGRAFTS: FOLLOW-UP AT A MEAN OF TWENTY-TWO YEARS. *J BONE JOINT SURG AM.* 2014;96:1101-7.
46. SHASHA N, KRYWULAK S, BACKSTEIN D, PRESSMAN A, GROSS AE. LONG-TERM FOLLOW-UP OF FRESH TIBIAL OSTEOCHONDRAL ALLOGRAFTS FOR FAILED TIBIAL PLATEAU FRACTURES. *J BONE JOINT SURG AM.* 2003;85-A(SUPPL 2):33-9.

## PATIENTS SPECIFIC CUTTING GUIDES ARE HELPFUL TOOLS FROM SIMPLE TO COMPLEX INTRA-ARTICULAR HIGH TIBIAL OSTEOTOMIES

Christophe Jacquet<sup>1,2</sup>, Philippe Berton<sup>3</sup>, Mathias Donnez<sup>3</sup>, Akash Sharma<sup>1</sup>, Kristian Kley<sup>2,4</sup>

Adrian Wilson<sup>2,4</sup>, Simone Cerciello<sup>1</sup>, Sébastien Parratte<sup>1,2</sup>, Matthieu Ollivier<sup>1,2</sup>

1- Institute of movement and locomotion Department of Orthopedics and Traumatology, St Marguerite Hospital, 270 Boulevard Sainte Marguerite, BP 29 13274 Marseille, France.

2- Aix Marseille Univ, APHM, CNRS, ISM, Sainte-Marguerite Hospital, Institute for Locomotion, Department of Orthopedics and Traumatology, Marseille, France.

3- Newclip Techniques, Haute Goulaine, France.

4- The Wellington Hospital, Wellington Place, St. John's Wood, London, UK.

### INTRODUCTION

The aim of medial opening-wedge and lateral closing tibial osteotomies is to correct varus alignment in the lower limb to treat overload in the medial compartment of the knee joint [1,2]. In the last decade, medial opening-wedge high tibial osteotomy (OW-HTO) has gained increasing popularity, as more and more studies continue to report good post-operative outcomes with fewer complications [2]. Accurate correction in all three spatial planes is a pivotal factor to obtain good clinical outcomes [3]. To achieve the ideal planned correction, various planning methods, surgical techniques using different instrumentations have been developed. This includes conventional methods (with various intraoperative techniques to assess lower-limb alignment), computer-assisted surgery [4,5] and recently the use of patient-specific cutting guides (PSCG) [6–8]. We started using PSCG in 2015 [9] and recently published 2 years results of our 100 first patients [10], as well as our learning curve using this philosophy in regular OW-HTO [11].

Our experience drove us to a better understanding of Maths

and Biomechanical basis of osteotomies thanks to the extensive 3D planning and virtual osteotomy prior to the surgery. Thus, we challenged ourselves to perform more and more complex surgeries using these new tools with 3D virtual planning and PSCG to perform proper bone cuts and fixation of the plates. The aim of this paper is to describe our experience and share some practical tips and tricks for these new technologies for OW-HTO.

### Basics correction osteotomies

#### Indication

In the vast majority of cases knee osteotomy aims to correct an extra-articular deformity by shifting the mechanical axis from the overloaded femoro-tibial compartment to the contralateral side to unload cartilage and subchondral bone [12]. By correcting a pre-existing tibial or femoral metaphyseal abnormality the natural evolution of knee arthritis might be slowed down. The Hip-Knee-Ankle (HKA) angle is usually used to estimate the overall alignment of the lower limb. This angle represents the

result of three components: the bony alignment of the femur and tibia as well as the intra-articular deformity resulting from articular surface wear at the concave and soft-tissue laxity on the convex side of the deformity. To allow proper planning of the bony correction the deformity analysis, introduced by D. Paley long time ago, is mandatory [13]. This includes the Lateral Distal Femoral Angle (LDFA), the Medial Proximal Tibia Angle (MPTA) as well as the Joint Line Convergence Angle (JLCA). The LDFA is defined by the angle between the femoral mechanical axis and the articular surface of the distal femur. The MPTA is defined by the angle between the tibial mechanical axis and the articular surface of the proximal tibia. The JLCA best reflects cartilage wear, meniscus loss and soft-tissue laxity of the contralateral side. (Figure 1 A-B-C)

#### Conventional planning

When dealing with a misaligned lower limb, the first step is to analyze if the deformity is located at the Tibia, Femur or both, which will influence where the osteotomy has to be performed. Not all varus knees have the deformity on the tibia only. 10-15% will need a femur or a combined femur and tibia

osteotomy for correction, otherwise the jointline will be significantly malorientated. The next step is to decide for the proper postoperative frontal alignment and therefore to plan the desired correction. The planning must be performed on standardized full leg weight bearing X-rays [14]. Traditionally the new weight-bearing line should be within the "Fujisawa" point, which is 62% and 65% of the tibial plateau (with the medial side set at 0% and the outermost lateral aspect at 100%) [15]. Based on this point it is then possible to calculate the amount of correction needed in the frontal plane. One of the most common used technique for this correction angle  $\alpha$  calculation is the Miniaci method [16] (Fig 1 D-E). Any existing soft tissue laxity on the concave side of the deformity (JLCA > 2 mm) has to be included in this bony correction angle calculation, otherwise the leg might be overcorrected.

### 3-D PLANNING

The described conventional planning is focusing on the frontal plane only. PSCG includes the option of a much more sophisticated 3D planning procedure (Figure 1F). This allows in more



# ISAKOS CONGRESS 2021



**Cape Town**  
South Africa  
Nov 27 – Dec 1



#ISAKOS2021

[isakos.com/2021congress](https://isakos.com/2021congress)

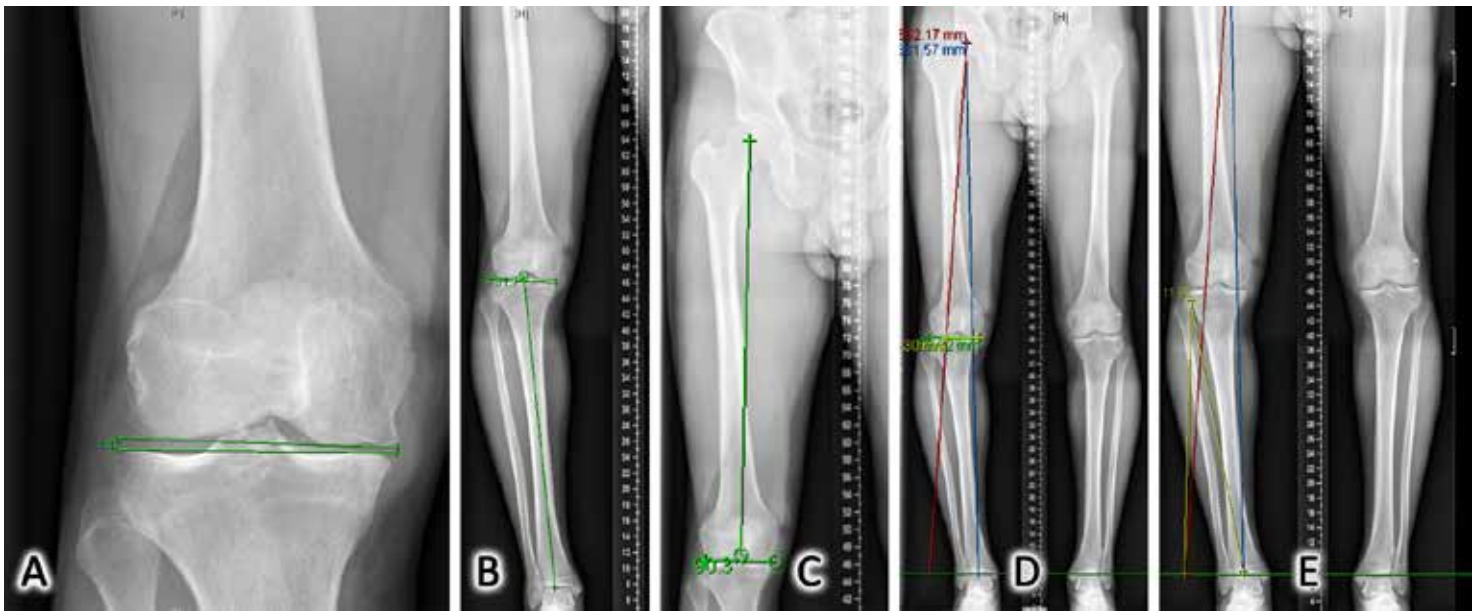


Figure 1 : Measurement of angles

A and B: Joint Line Congruency Angle (JLCA 3.3 mm) and Medial Proximal Tibia Angle (MPTA 82°)

C: Lateral Distal Femoral Angle (LDFA 90°)

D and E: Calculation of correction using the Miniaci Method:

First draw the lower limb weight bearing blue line (line passing from the center of the hip to the center of the ankle).

Second draw correction red line (connecting the hip center, passing through the selected “Fujisawa” point and down to the ankle level)

Third draw a crossing green line (parallel to the ground passing through the center of the ankle)

Fourth draw the two-connection yellow lines (First line connecting the future lateral tibial hinge point and the center of the ankle joint. Second line connecting the tibial hinge with the intersection of the correction red line with the green crossing line)

The angle formed between those two yellow lines represents the predicted correction angle (angle  $\alpha$ ).

complex cases, osteotomies to be used for correction of ligament insufficiencies, treat intra-articular deformities or correct lower-limb torsional malalignments. In those cases, additional measurements are needed (Figure 2A-B). For example, sagittal evaluation of the proximal tibia is mandatory to plan a slope modifying osteotomy in case of chronic cruciate ligaments insufficiencies or correction of sagittal bony deformity with a pathological slope. For ACL insufficiencies we reduce and for PCL insufficiencies we increase the natural slope. The aim of pathological slope correction is to end up with a normal value close to 7° [17]. Regarding varus deformities we usually aim for a correction of the Mikulicz line reaching a Fujizawa point between 55 to 65% based on cartilage and meniscus status. The CT scan included in the PSCG technique will also help surgeons to define quality and position of previous bone tunnels. For combined ACL reconstructions with OW-HTO the tunnel placement in reference to the screws can be planned also.

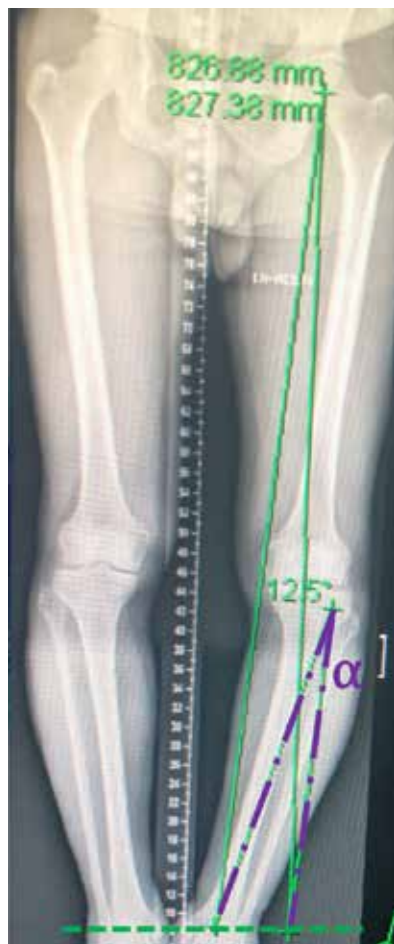

Figure 1F : Example of a predicted correction angle (angle  $\alpha$ ), following the Miniaci Method

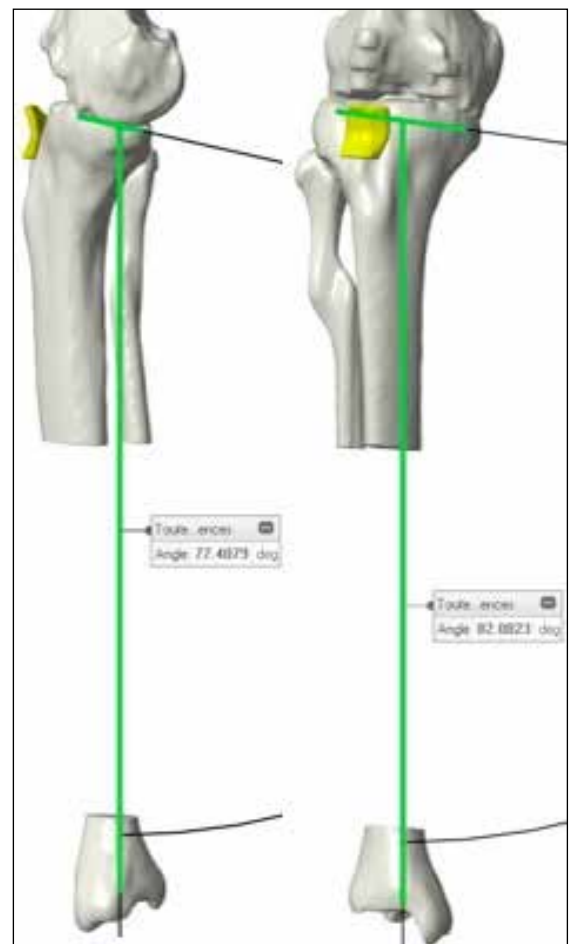


Figure 2 A-B : Example of a 3D planning of complex osteotomy which needs a correction of a pathological slope with 13°



## VIRTUAL OSTEOTOMY

This is one of the main advantages of the PSCG technique which allows a more sophisticated 3D planning.

Osteotomy correction depend on three connected parameters:

### - Cutting plane angulation:

This represents the angulation of the cutting plane with frontal and sagittal tibial mechanical axes (Figure 3). Every displacement of the sawing plane angulation away from a perfect perpendicular angle with the tibial mechanical axis and perfect parallel plane with the tibial plateau influence sagittal and frontal correction.

- **Hinge positions:** A more posterior hinge will decrease the tibial slope and a more anterior one will increase the tibial slope as compared to more central positions (Figure 4)

- **Wedge positions:** A more posterior wedge will decrease the tibial slope and a more anterior wedge will increase the tibial slope as compared to more central positions.

Those three elements are used in the 3D preoperative planning to obtain the desired correction (Figure 5) and to modify intentionally MPTA and slope when needed.

## TECHNICAL CONCEPT PSCG

The global idea behind the PSCG is based on three crucial points,

- **Positing two k-wires** to verify PSCG position and secure Tibia's hinge from sawing (Figure 6)

- **Saw blade guidance** to allow very accurate angulation relatively to tibial morphological parameters (Figure 7)

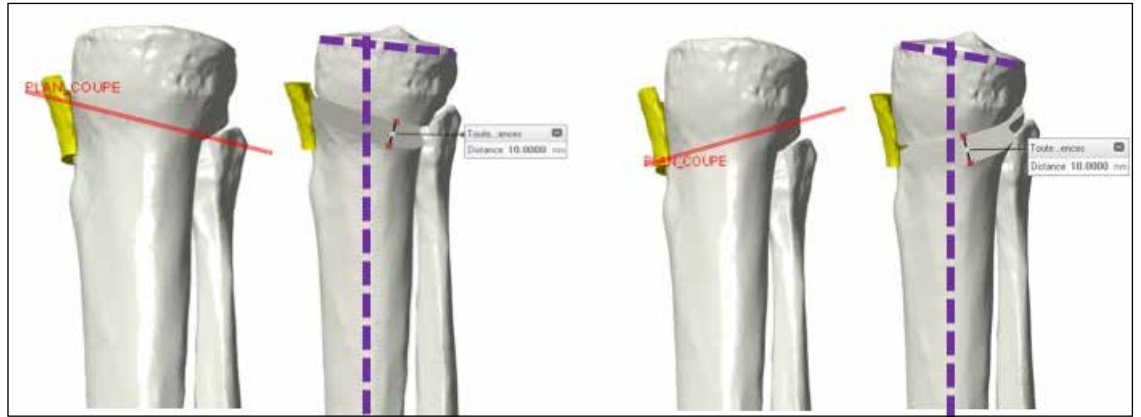


Figure 3: 3D planning of the cutting plane

Every displacement of the sawing plane angulation away from a perfect perpendicular angle with the tibial mechanical axis and perfect parallel plane with the tibial plateau influence sagittal and frontal correction.

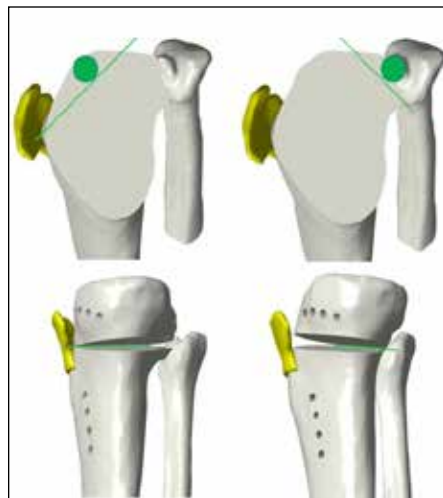

Figure 4: 3D Planning of the lateral hinge position

The example shows the impact of the hinge position on the tibial slope. A more posterior hinge increases the tibial slope and a more anterior one decreases the tibial slope as compared to more central positions

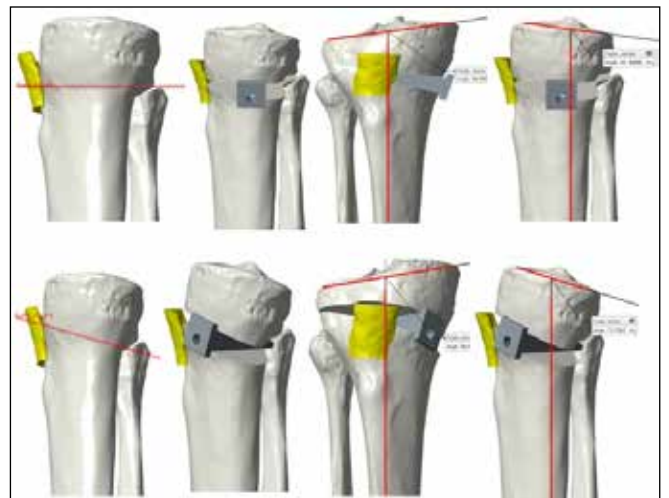

Figure 5: Influence of hinge position and cutting plane on MPTA and slope. The two 3D planning examples (upper and lower line) with a modification of the hinge position and the cutting plane angulation show their influences on the MPTA and slope.

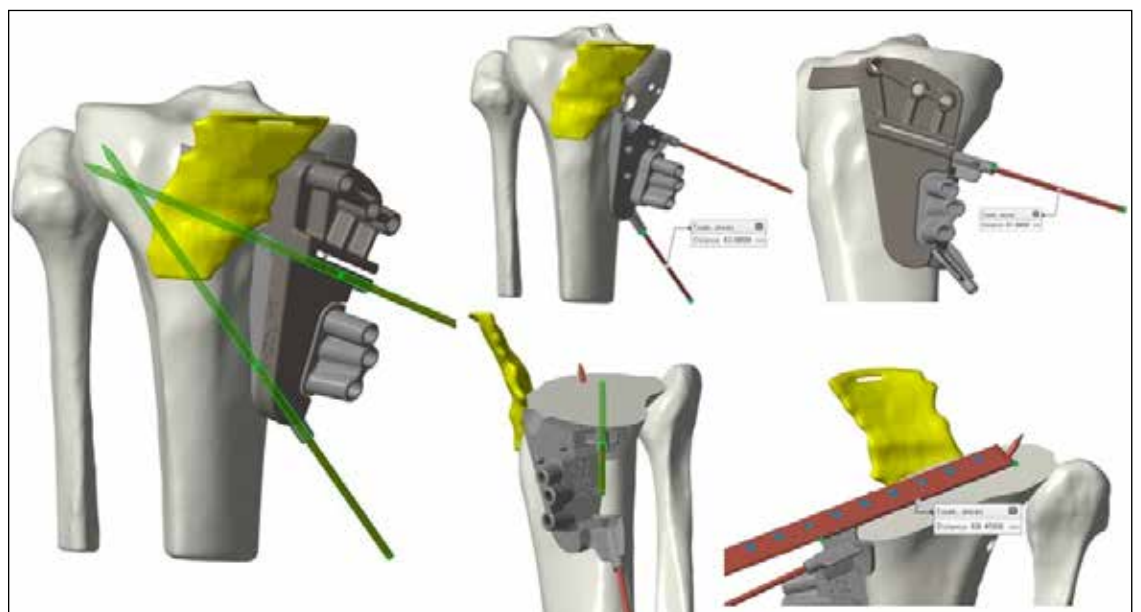


Figure 6: Temporary PSCG fixation - Example shows the 3D fixation with the two k-wires

- Map of 6 to 8 screw holes to allow guided drilling for screw holes which will match to the screw position of the final plate after the correction (Figure 8)

The PSCG concepts allows

- Deep surface mirroring of the tibial bone to easily find its adequate position

- Anterior and posterior legs to be placed below the patellar tendon and anterior to the released posterior oblique ligament.

- Two or more K-wires holes to fix temporary the guide on the tibia, verify its position using fluoroscopy and avoid saw blade to change direction or to cut the hinge unintentionally.

- A saw blade slot to insert the saw and perform mono or biplanar cuts.

- Secure the system onto the tibial bone for sawing using the 6 to 8 holes which are prepared for the future final screws position

- Option for additional slots such as Ligament or Meniscus Tunnel driller, articular cutting bloc, etc....

This PSCG is not protecting soft-tissues or posterior neurovascular structures during sawing by itself. Therefore, a modification of the traditional antero-medial or anterolateral

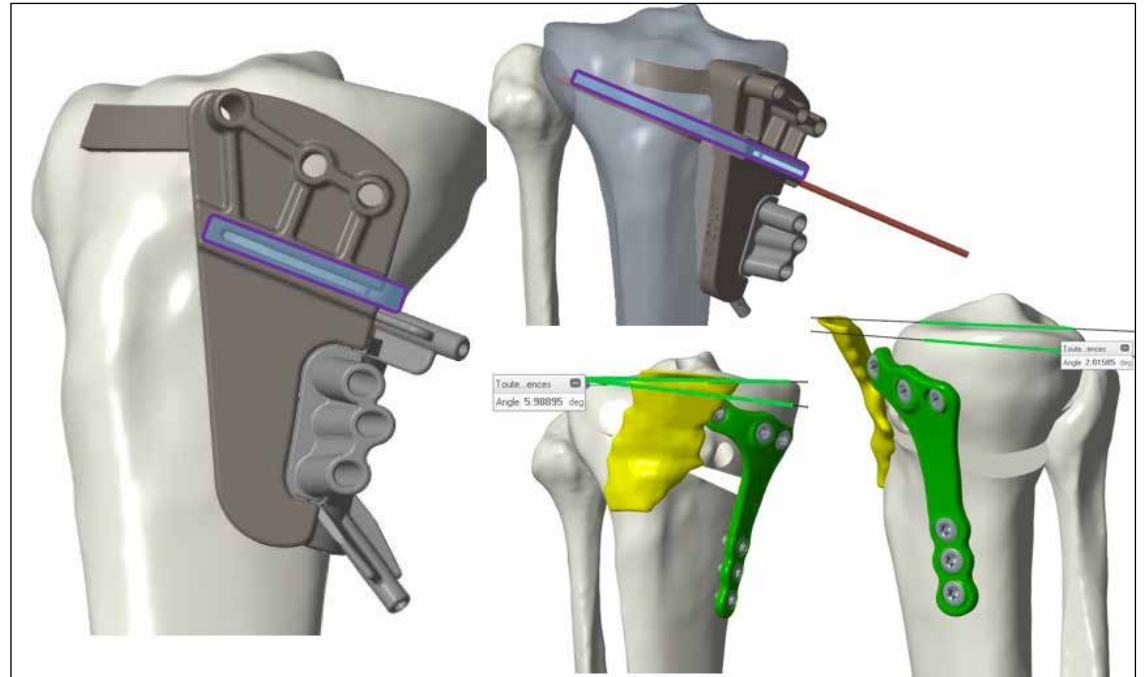


Figure 7: Saw blade guidance and final plate fitting  
Example shows the 3D representation of the saw blade guidance and fitting of the final blade

approach is mandatory to achieve an optimal positioning and a safe procedure.

## SURGICAL TIPS AND TRICKS

Approach, MCL, Pes anserinus and posterior Neurovascular structure management.

Medial Collateral Ligament (MCL) release and posterior neurovascular structures (NVS) protection during OW-HTO remain two stressful steps.

### Approach:

A medial skin incision is performed starting 1cm below the femoro-tibial joint line and extending 8-10 cm toward the distal tibia, slightly more posterior than usual to get access the postero-medial corner. (Figure 9) A Blunt dissection allows to palpate and mark the Patellar tendon to prepare some space for PSCG anterior leg positioning. The pes anserinus is dissected and retracted posteriorly. Starting at the posterior aspect of the MCL a periosteal elevator is used to dissect the

soft tissue until the posterior cortex of the tibia is reached and the popliteus muscle can be carefully released. This elevator is left in place to guide the posterior-tissue retractor (PTR) between the posterior cortex and the popliteus muscle (this step can be done in flexion to facilitate insertion). (Figure 10) The posterior Oblique Ligament (POL) is released carefully using a periosteal elevator. The two posterior legs of the PSCG will need a sufficient amount of POL release to allow posterior retractor to be inserted easily.

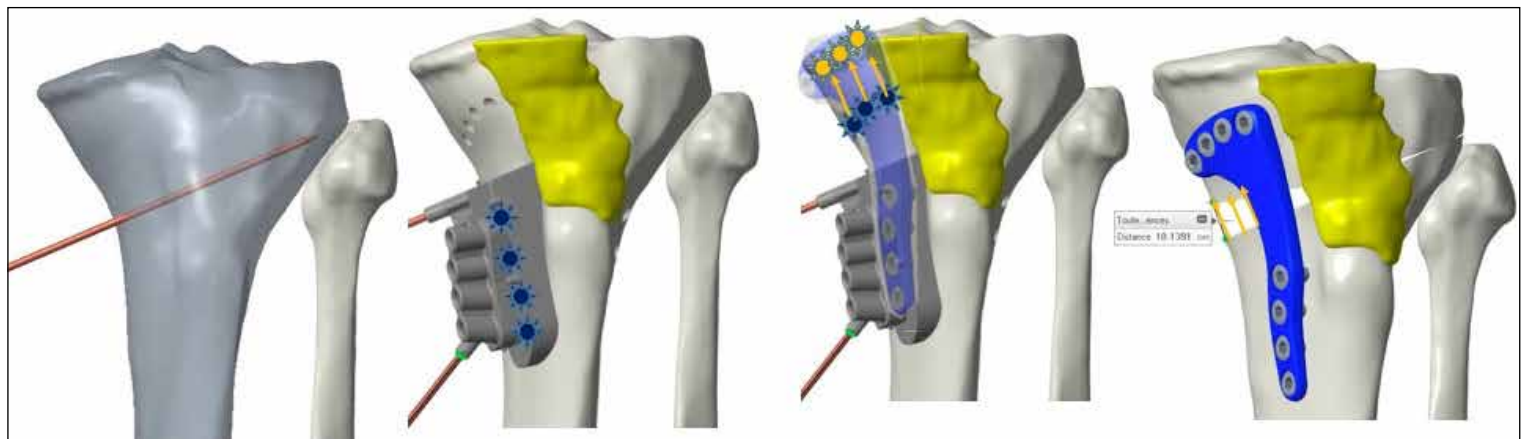


Figure 8: Fitting of pre-drilled holes to the final plate  
Example shows 3D fitting of the pre-drilled holes to the final holes and plate after the correction allowing stable fixation by screws

## Positioning PSCG and Osteotomy:

Once the PSCG is inserted two K-wire are drilled in the dedicated holes, for temporary fixation. This should be carefully controlled by fluoroscopy (Figure 11) to confirm the optimal position of the Guide. Then the screw holes are drilled, and the guide is rigidly fixed on the tibia using six 4 mm Pins. During the sawing process a small Hohmann retractor is used to retract the MCL, to get good access to the cutting plane.

Once the Saw-cut has been done, the PSCG is removed leaving only the hinge K-wire inside the tibia. A metal ruler or chisel is used to confirm that all the posterior cortex has been completely cut, by feeling a metal contact on the posterior retractor in place.

## Opening Wedge and Fixation

The opening is performed by placing the spreader posterior to the MCL. Depending of the amount of opening the MCL will be tensioned and need some release. The additional tension of the MCL can be sensed easily with the fingertip. We manage the necessary release of the MCL using the pie-crusting technique. For limited amount of corrections, a small release of the posterior fibers allows sufficient lengthening and maintain integrity of the MCL to cover the osteotomy plate. The correction is performed sufficiently when the previously drilled holes in the tibia bone are fitting to the selected holes in the plate. The plate is then finally fixed to the tibia bone by using all drilled screw holes to sufficiently hold the planned correction. (Figure 12)

## COMPLEX CASES

As PSCG are also “Surgeon Specific” and very versatile, progressive modifications have been done during the last years.

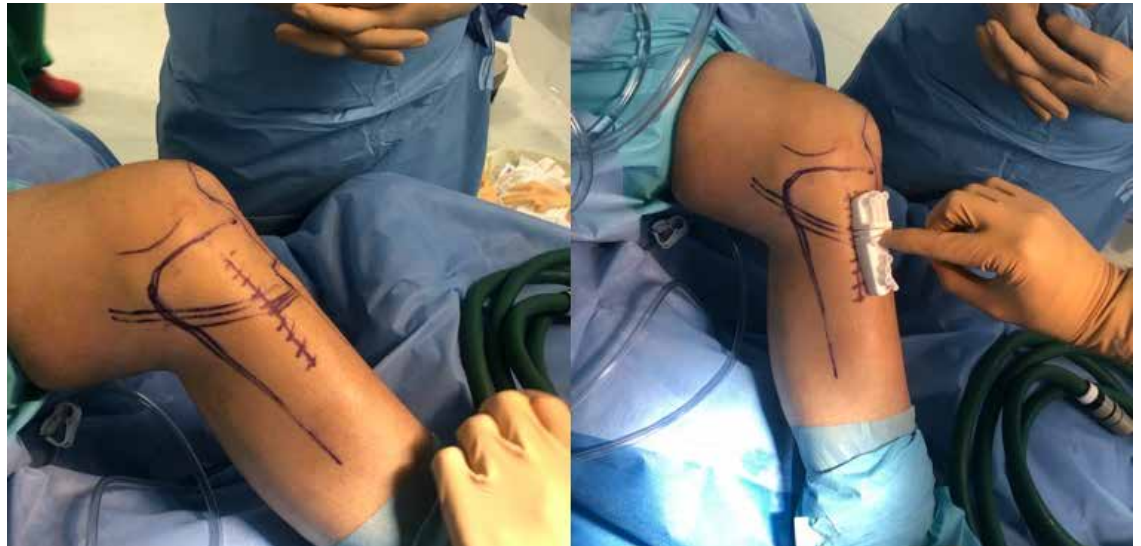

Figure 9: Skin incision for medial approach  
Starting 1cm below the femoro-tibial joint line and extending 8-10 cm toward the distal tibia

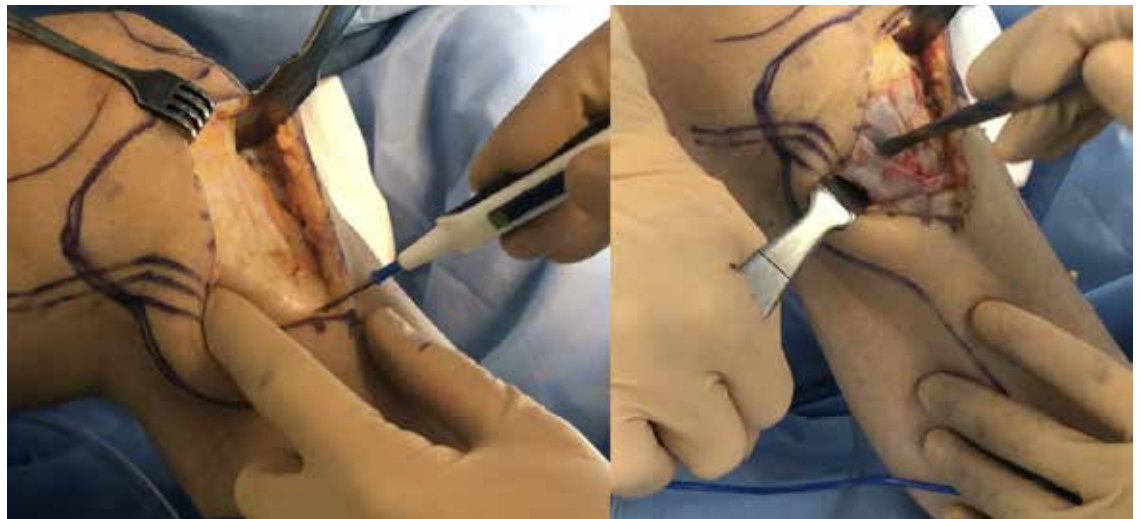

Figure 10: Medial approach for the osteotomy:  
The pes anserinus is dissected and retracted posteriorly. Starting at the posterior aspect of the MCL a periosteal elevator is used to dissect the soft tissue until the posterior cortex of the tibia is reached and the popliteus muscle carefully released. This elevator is left in place to guide the posterior-tissue retractor (PTR) between the posterior cortex and the popliteus muscle (this step can be done in flexion to facilitate insertion)

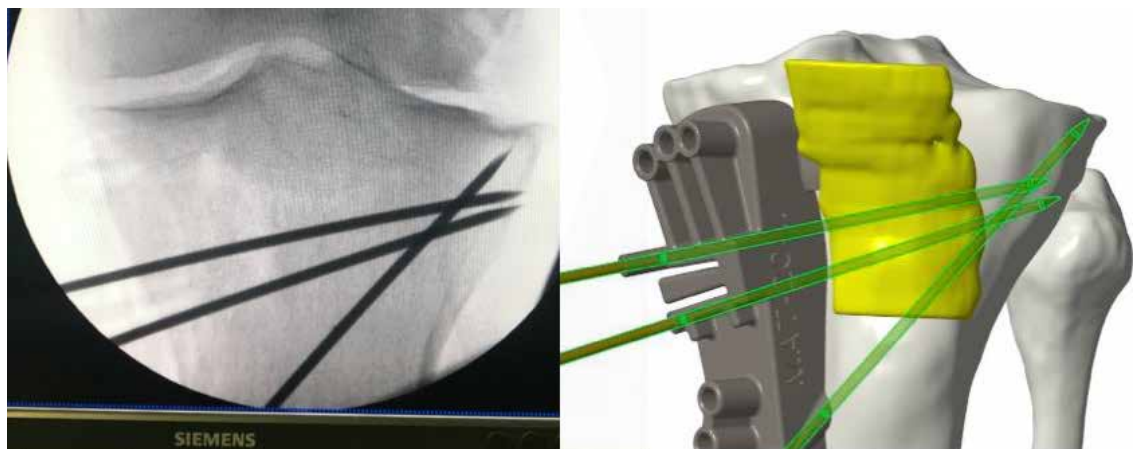


Figure 11: Fluoroscopic control of the optimal position of the PSCG  
Note the perfect correspondence of the fluoro to the planning picture

This allows us to perform a more minimally invasive, Hinge Protective [18,19] and combined single stage surgery (ACL – PCL – Cartilage – Meniscus repair/reconstruction) in cases often requiring two or more staged procedures in the past.

For Example, combined ACL + OW-HTO are easily done using a dedicated tunnel driller implemented during 3D Planning. This modification of the PSCG ensure the surgeon not to hit the osteotomy screws when drilling the ACL or PCL tunnel. (Figure 13) Intra-articular osteotomies are recommended to correct either intra-articular deformities (such as post-traumatic malalignment) or severe metaphyseal varus (such as Blount Disease for example). Chiba et al [20] described their L-inverted shape osteotomy to correct metaphyseal varus using an elevation of the medial or lateral tibial plateau alone in combination with a rotational correction to allow the upper tibial plateau to be perpendicular to the diaphysis (figure 14). This represents a very complex surgery and requires two cuts: one horizontal and one vertical (inside of the joint) to completely separate the hemi-plateau from the tibia (Figure 15). Once adapted PSCGs are fantastic tools to perform

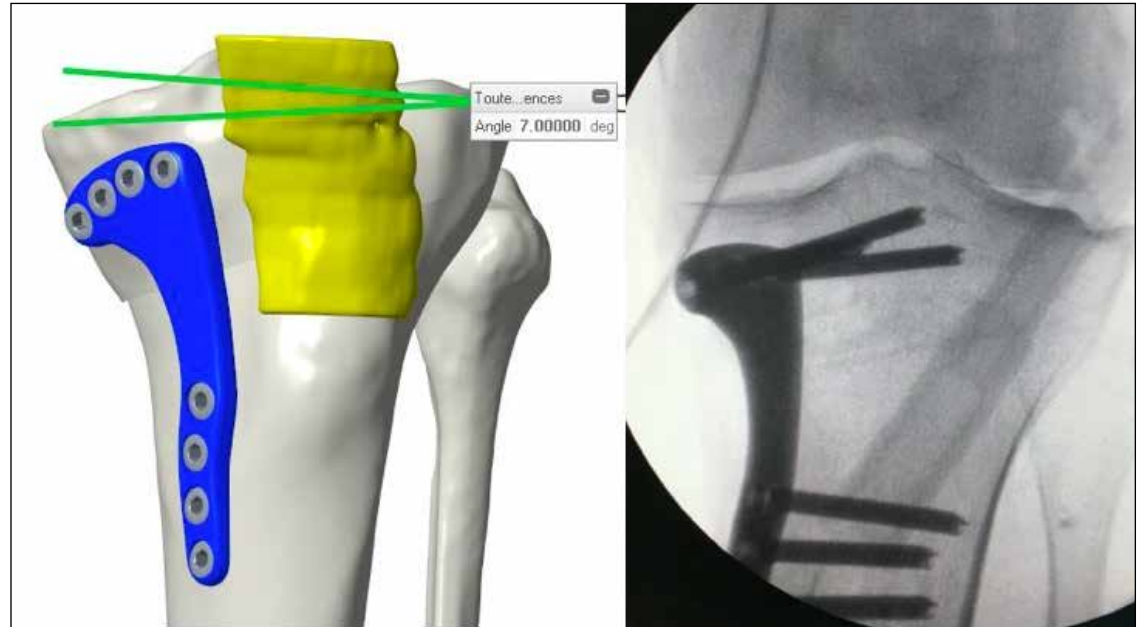


Figure 12: Fluoroscopic control of the final fixation

this complex intra-articular L-Inverted correction. We have been using it in abnormal tibial deformities (Figure 16) and after tibial plateau fractures with hemi-plateau impression. The protecting K-wires are multiplied to protect also the neurovascular bundles during the risky vertical cut. Specific 3D printed wedges can be prepared to position the hemi-plateau prior to final fixation. Furthermore, the PSCG represents sometimes a good option to prepare an ideal bone wedges from a femoral head allograft to ensure perfect gap filling.

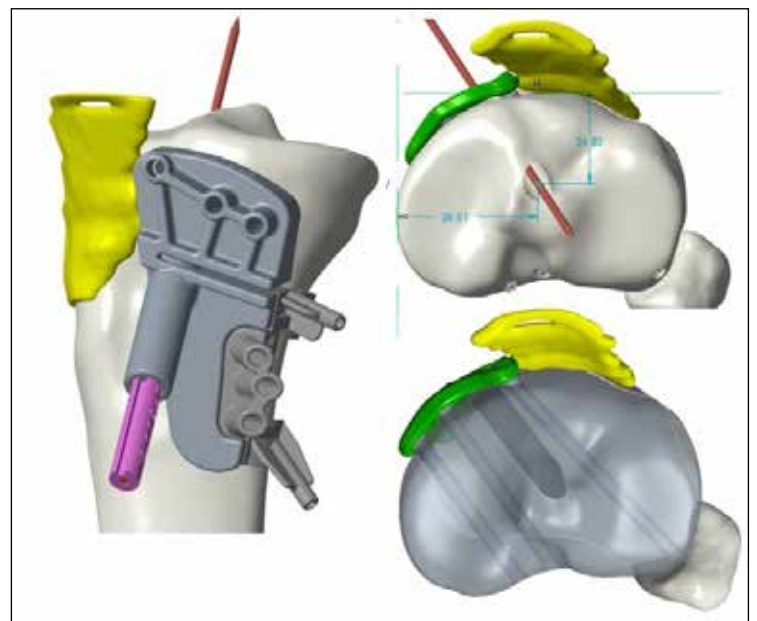


Figure 13: Combined ACL & OW-HTO

Example shows the 3D planning of the tunnel placement for the combined ligament reconstruction using the cutting guide to perform the tibial tunnel

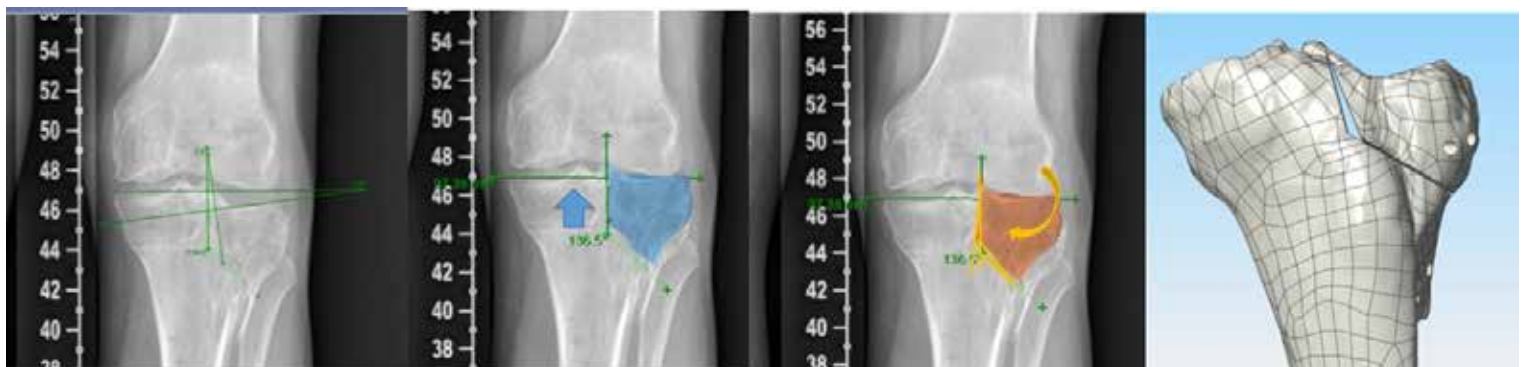


Figure 14: Lateral Hemi-ostotomy planning

Example shows L-inverted shape osteotomy to correct metaphysal post-traumatic varus using an elevation of the lateral tibial hemi-plateau alone in combination with a rotational correction allowing the upper tibial plateau to be perpendicular to the diaphysis.

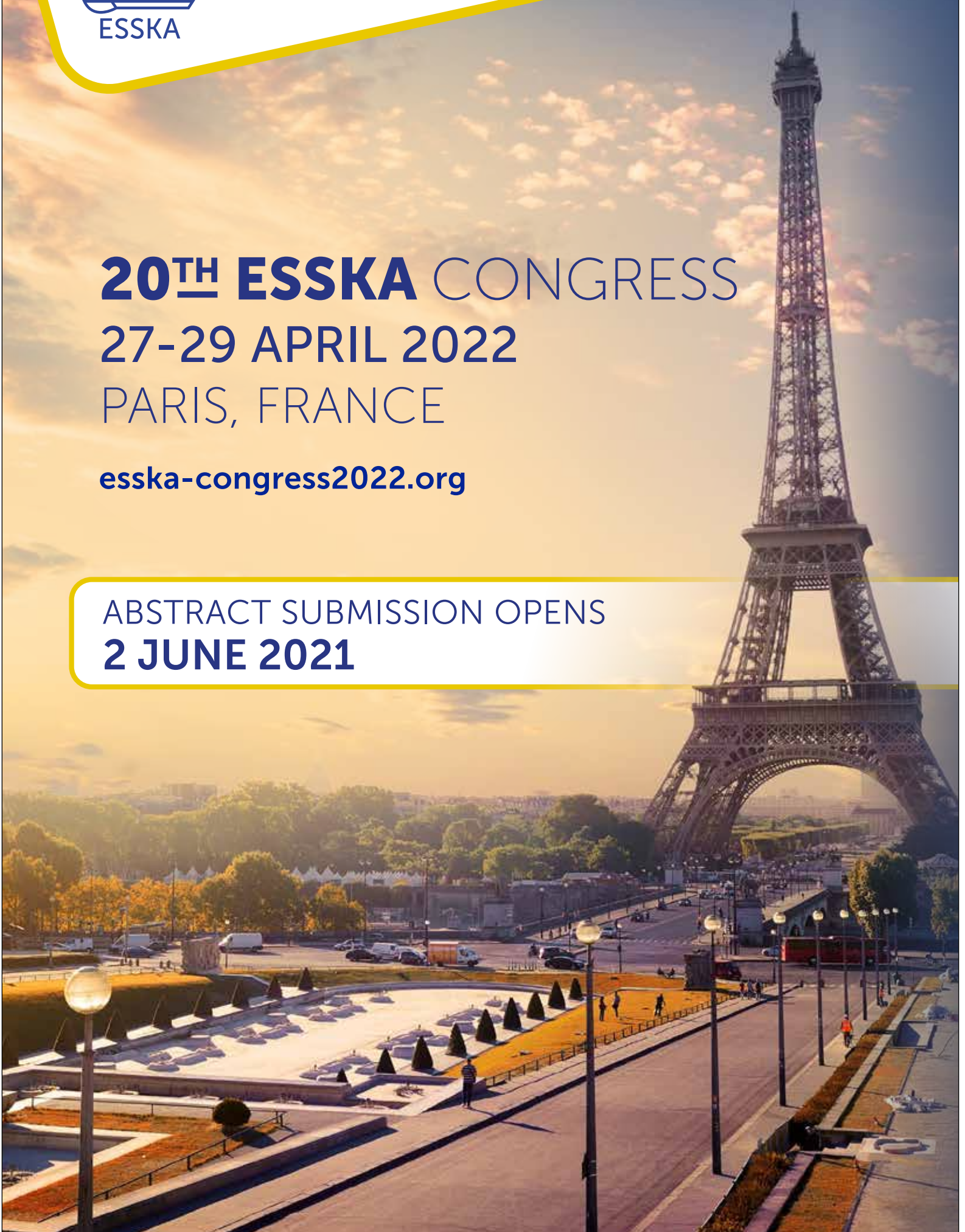

**Science Opens  
the Mind**

**20<sup>TH</sup> ESSKA CONGRESS**  
**27-29 APRIL 2022**  
PARIS, FRANCE

[esska-congress2022.org](https://esska-congress2022.org)

ABSTRACT SUBMISSION OPENS  
**2 JUNE 2021**



## OWN PRELIMINARY RESULTS

We performed more than 300 PSCG osteotomy cases in the last 5 years, and we already published the accuracy of the correction obtained in both specimens [9], ten first [7] and hundred first HTO and DFO patients [10,21] as well as the learning curve of the system [11]. We also investigated on several improvements such as the hinge protective K-wire [18,19] or the influence of sawblade geometry [22]. Overall, the precision of the system in both coronal and sagittal plane was  $1 \pm 1^\circ$  and after 10 cases the mean operative

time dropped below 30 minutes with 6 intraoperative fluoroscopic images taken only [10,11]. The clinical results of our patients involved in impact sports showed better results compared with patients undergoing unicompartmental knee arthroplasty [23].

## FUTURE FOR PSCG

We have been using PSCG for 5 years. Our understanding and performing of osteotomies has been drastically changed by 3D planning and Virtual Osteotomy. We have learned how much the ideal position of the hinge, direction of the cutting plane and insertion of the wedge influence

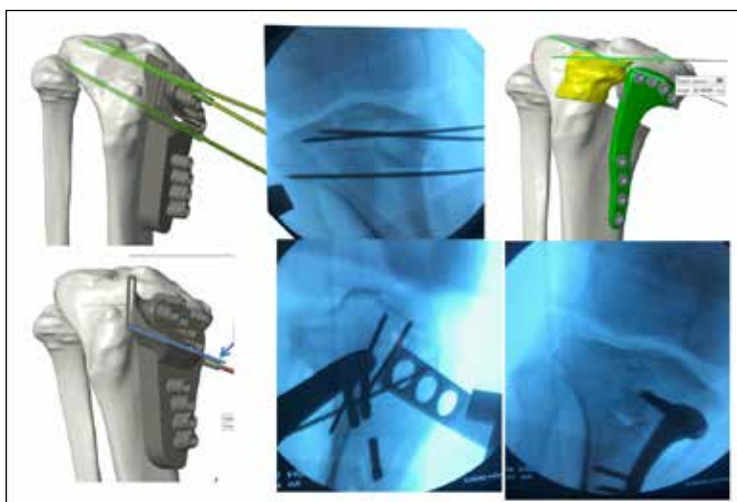


Figure 15: Planning & fluoro views of case from fig 14. Example shows the L-inverted shape osteotomy using the cutting guide. The correction implies creation of two cuts: one horizontal and one vertical (inside of the joint) to completely separate the selected tibial plateau from the tibia.

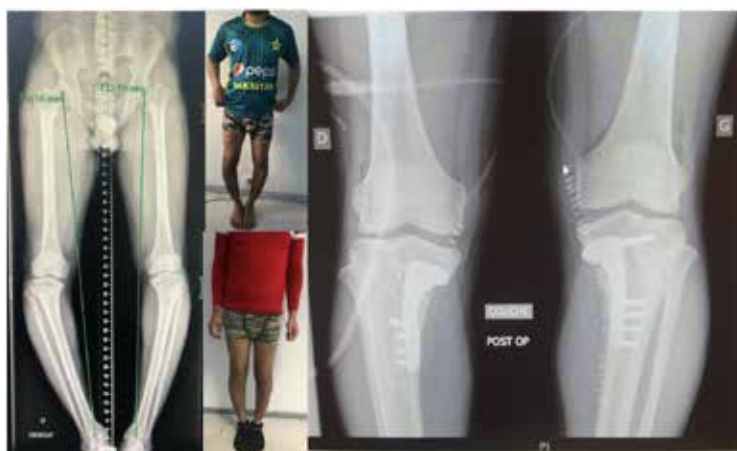

Figure 16: Case of a bilateral Blount disease. This deformity required a bilateral double L-inverted shape osteotomy using the PSCG system.

## References

- [1] AMIS AA. BIOMECHANICS OF HIGH TIBIAL OSTEOTOMY. *KNEE SURG SPORTS TRAUMATOL ARTHROSC* 2013;21:197–205. [HTTPS://DOI.ORG/10.1007/S00167-012-2122-3](https://doi.org/10.1007/s00167-012-2122-3).
- [2] BODE G, VON HEYDEN J, PESTKA J, SCHMAL H, SALZMANN G, SÜDKAMP N, ET AL. PROSPECTIVE 5-YEAR SURVIVAL RATE DATA FOLLOWING OPEN-WEDGE VALGUS HIGH TIBIAL OSTEOTOMY. *KNEE SURG SPORTS TRAUMATOL ARTHROSC* 2015;23:1949–55. [HTTPS://DOI.ORG/10.1007/S00167-013-2762-Y](https://doi.org/10.1007/s00167-013-2762-y).
- [3] BERMAN AT, BOSACCO SJ, KIRSHNER S, AVOLIO A. FACTORS INFLUENCING LONG-TERM RESULTS IN HIGH TIBIAL OSTEOTOMY. *CLIN ORTHOP RELAT RES* 1991;192–8.
- [4] SARAGAGLIA D, ROBERTS J. NAVIGATED OSTEOTOMIES AROUND THE KNEE IN 170 PATIENTS WITH OSTEOARTHRITIS SECONDARY TO GENU VARUM. *ORTHOPEDICS* 2005;28:S1269–1274.
- [5] SARAGAGLIA D, CHEDAL-BORNU B, ROUCHY RC, RUBENS-DUVAL B, MADER R, PAILHÉ R. ROLE OF COMPUTER-ASSISTED SURGERY IN OSTEOTOMIES AROUND THE KNEE. *KNEE SURG SPORTS TRAUMATOL ARTHROSC* 2016;24:3387–95. [HTTPS://DOI.ORG/10.1007/S00167-016-4302-Z](https://doi.org/10.1007/s00167-016-4302-z).
- [6] VICTOR J, PREMANATHAN A. VIRTUAL 3D PLANNING AND PATIENT SPECIFIC SURGICAL GUIDES FOR OSTEOTOMIES AROUND THE KNEE: A FEASIBILITY AND PROOF-OF-CONCEPT STUDY. *BONE JOINT J* 2013;95-B:153–8. [HTTPS://DOI.ORG/10.1302/0301-620X.95B11.32950](https://doi.org/10.1302/0301-620X.95B11.32950).
- [7] MUNIER M, DONNEZ M, OLLIVIER M, FLECHER X, CHABRAND P, ARGENSON J-N, ET AL. CAN THREE-DIMENSIONAL PATIENT-SPECIFIC CUTTING GUIDES BE USED TO ACHIEVE OPTIMAL CORRECTION FOR HIGH TIBIAL OSTEOTOMY? PILOT STUDY. *ORTHOP TRAUMATOL SURG RES* 2017;103:245–50. [HTTPS://DOI.ORG/10.1016/J.OTSR.2016.11.020](https://doi.org/10.1016/j.otsr.2016.11.020).
- [8] PÉREZ-MAÑANES R, BURRÓ JA, MANAUTE JR, RODRIGUEZ FC, MARTÍN JV. 3D SURGICAL PRINTING CUTTING GUIDES FOR OPEN-WEDGE HIGH TIBIAL OSTEOTOMY: DO IT YOURSELF. *J KNEE SURG* 2016;29:690–5. [HTTPS://DOI.ORG/10.1055/S-0036-1572412](https://doi.org/10.1055/s-0036-1572412).
- [9] DONNEZ M, OLLIVIER M, MUNIER M, BERTON P, PODGORSKI J-P, CHABRAND P, ET AL. ARE THREE-DIMENSIONAL PATIENT-SPECIFIC CUTTING GUIDES FOR OPEN WEDGE HIGH TIBIAL OSTEOTOMY ACCURATE? AN IN VITRO STUDY. *J ORTHOP SURG RES* 2018;13:171. [HTTPS://DOI.ORG/10.1186/S13018-018-0872-4](https://doi.org/10.1186/s13018-018-0872-4).
- [10] CHAOUCHÉ S, JACQUET C, FABRE-AUBRESPY M, SHARMA A, ARGENSON J-N, PARRATTE S, ET AL. PATIENT-SPECIFIC CUTTING GUIDES FOR OPEN-WEDGE HIGH TIBIAL OSTEOTOMY: SAFETY AND ACCURACY ANALYSIS OF A HUNDRED PATIENTS CONTINUOUS COHORT. *INT ORTHOP* 2019. [HTTPS://DOI.ORG/10.1007/S00264-019-04372-4](https://doi.org/10.1007/s00264-019-04372-4).
- [11] JACQUET C, SHARMA A, FABRE M, EHLINGER M, ARGENSON J-N, PARRATTE S, ET AL. PATIENT-SPECIFIC HIGH-TIBIAL OSTEOTOMY'S "CUTTING-GUIDES" DECREASE OPERATING TIME AND THE NUMBER OF FLUOROSCOPIC IMAGES TAKEN AFTER A BRIEF LEARNING CURVE. *KNEE SURG SPORTS TRAUMATOL ARTHROSC* 2019. [HTTPS://DOI.ORG/10.1007/S00167-019-05637-6](https://doi.org/10.1007/s00167-019-05637-6).
- [12] MAQUET P. THE BIOMECHANICS OF THE KNEE AND SURGICAL POSSIBILITIES OF HEALING OSTEOARTHRITIC KNEE JOINTS. *CLIN ORTHOP RELAT RES* 1980;102–10.
- [13] PALEY D, HERZENBERG JE, TETSWORTH K, MCKIE J, BHAVE A. DEFORMITY PLANNING FOR FRONTAL AND SAGITTAL PLANE CORRECTIVE OSTEOTOMIES. *ORTHOP CLIN NORTH AM* 1994;25:425–65.
- [14] LEE D-H, HAN S-B, OH K-J, LEE JS, KWON J-H, KIM J-I, ET AL. THE WEIGHT-BEARING SCANOGRAM TECHNIQUE PROVIDES BETTER CORONAL LIMB ALIGNMENT THAN THE NAVIGATION TECHNIQUE IN OPEN HIGH TIBIAL OSTEOTOMY. *KNEE* 2014;21:451–5. [HTTPS://DOI.ORG/10.1016/J.KNEE.2012.09.003](https://doi.org/10.1016/j.knee.2012.09.003).
- [15] FUJISAWA Y, MASUHARA K, SHIOMI S. THE EFFECT OF HIGH TIBIAL OSTEOTOMY ON OSTEOARTHRITIS OF THE KNEE. AN ARTHROSCOPIC STUDY OF 54 KNEE JOINTS. *ORTHOP CLIN NORTH AM* 1979;10:585–608.
- [16] MINIACI A, BALLMER FT, BALLMER PM, JAKOB RP. PROXIMAL TIBIAL OSTEOTOMY. A NEW FIXATION DEVICE. *CLIN ORTHOP RELAT RES* 1989;250–9.
- [17] WEINBERG DS, WILLIAMSON DFK, GEBHART JJ, KNAPIK DM, VOOS JE. DIFFERENCES IN MEDIAL AND LATERAL POSTERIOR TIBIAL SLOPE: AN OSTEOLOGICAL REVIEW OF 1090 TIBIAE COMPARING AGE, SEX, AND RACE. *AM J SPORTS MED* 2017;45:106–13. [HTTPS://DOI.ORG/10.1177/0363546516662449](https://doi.org/10.1177/0363546516662449).
- [18] DESSYN E, SHARMA A, DONNEZ M, CHABRAND P, EHLINGER M, ARGENSON J-N, ET AL. ADDING A PROTECTIVE K-WIRE DURING OPENING HIGH TIBIAL OSTEOTOMY INCREASES LATERAL HINGE RESISTANCE TO FRACTURE. *KNEE SURG SPORTS TRAUMATOL ARTHROSC* 2019. [HTTPS://DOI.ORG/10.1007/S00167-019-05404-7](https://doi.org/10.1007/s00167-019-05404-7).
- [19] GULAGACI F, JACQUET C, EHLINGER M, SHARMA A, KLEY K, WILSON A, ET AL. A PROTECTIVE HINGE WIRE, INTERSECTING THE OSTEOTOMY PLANE, CAN REDUCE THE OCCURRENCE OF PERIOPERATIVE HINGE FRACTURES IN MEDIAL OPENING WEDGE OSTEOTOMY. *KNEE SURG SPORTS TRAUMATOL ARTHROSC* 2019. [HTTPS://DOI.ORG/10.1007/S00167-019-05806-7](https://doi.org/10.1007/s00167-019-05806-7).
- [20] CHIBA K, YONEKURA A, MIYAMOTO T, OSAKI M, CHIBA G. TIBIAL CONDYLAR VALGUS OSTEOTOMY (TCVO) FOR OSTEOARTHRITIS OF THE KNEE: 5-YEAR CLINICAL AND RADIOLOGICAL RESULTS. *ARCH ORTHOP TRAUMA SURG* 2017;137:303–10. [HTTPS://DOI.ORG/10.1007/S00402-016-2609-3](https://doi.org/10.1007/s00402-016-2609-3).

OW-HTO's precision. The various modification that were incremented into our 3D planning now allow inclusion of Mikulicz line modification and will be converted into load changes on the medial and lateral tibial plateau (figure 17). For regular HTO, the PSCG devices have been adapted following surgeons' recommendation and desires. Most of us switch to smaller guides to minimize the size of the incision and the soft tissue release necessary for their positioning (FIGURE 18). For more complex cases, the only

limit is probably imagination from surgeons and engineers. Several surgeons challenged this new PSCG philosophy with their "worse cases" (figure 19). We do believe that PSCG will have a bright future in regular and especially for more complex cases. The small additional costs (around 300 €) are compensated by the drastic reduction of operative time and will probably conduce to better function and longer survivorship of the osteotomies. But this cost-effectiveness has to be proven by further studies in the future. ■

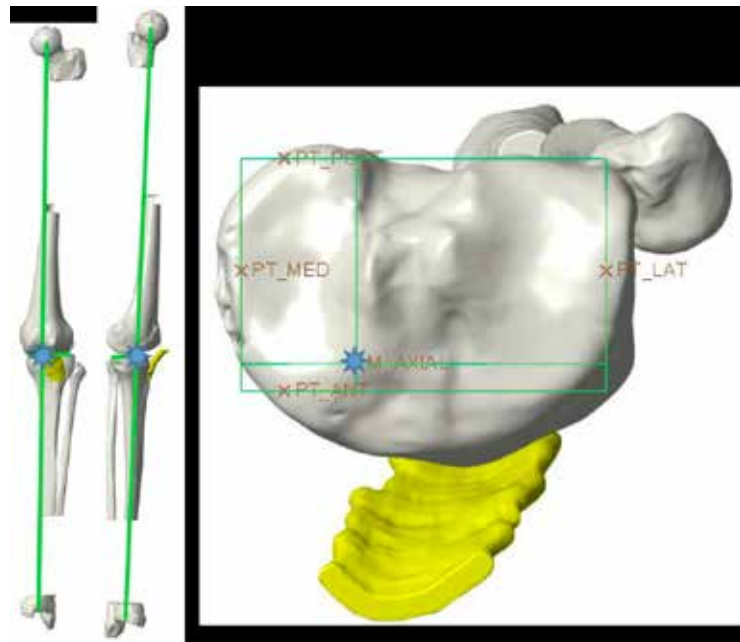


Figure 17: Virtual representation of the 3D Mikulicz line  
The example shows the maximal load point on the medial anterior Tibial Plateau before the correction

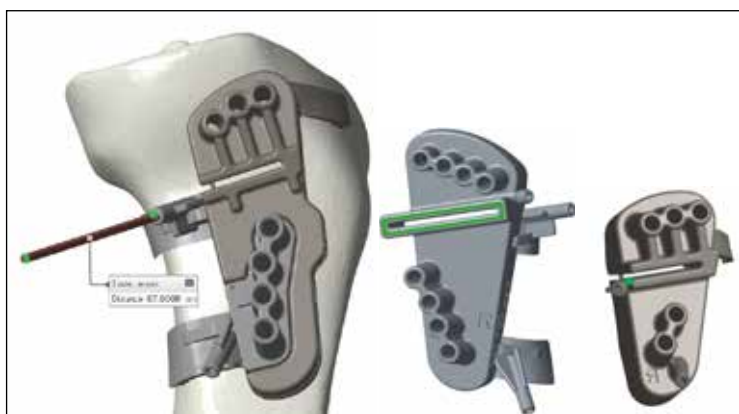

Figure 18. Evolution of PSCG's size  
A. Initial shape with 7-8 screw holes, one anterior and two posterior leg  
B. Actual shape for derotation no anterior leg  
C. Actual shape for OW-HTO no posterior leg and only two distal bores.

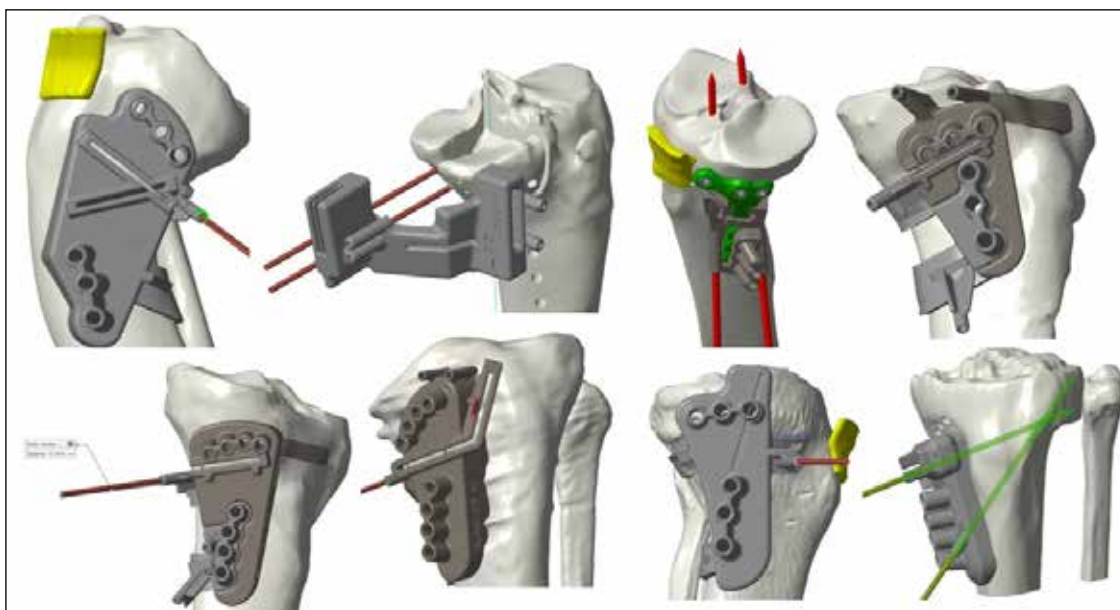


Figure 19: Virtual representation of different complex cases of osteotomy

- A : Congenital varus correction with slope deflexion osteotomy
- B : Post-traumatic Chiba osteotomy
- C : OW-HTO associated with meniscus allograft (the PSCG included meniscus transplants osseous tunnels).
- D : Post traumatic flexion osteotomy
- E: Congenital reverted slope correction
- F: Chiba osteotomy for massive metaphyseal varus deformity
- G : intra-articular osteotomy for post-traumatic deformity
- H: OW-HTO for post-traumatic deformity

## References

- [21] JACQUET C, CHAN-YU-KIN J, SHARMA A, ARGENSON J-N, PARRATTE S, OLLIVIER M. «MORE ACCURATE CORRECTION USING "PATIENT-SPECIFIC" CUTTING GUIDES IN OPENING WEDGE DISTAL FEMUR VARIZATION OSTEOTOMIES. INT ORTHOP 2018. [HTTPS://DOI.ORG/10.1007/S00264-018-4207-1](https://doi.org/10.1007/s00264-018-4207-1).
- [22] EHLINGER M, OLLIVIER M, COURSE S, GUERIN A, LANTZ É, ZAHRAA D, ET AL. EFFECT OF SAW BLADE GEOMETRY ON CRACK INITIATION AND PROPAGATION ON THE LATERAL CORTICAL HINGE FOR HTO: FINITE ELEMENT ANALYSIS. ORTHOP TRAUMATOL SURG RES 2019;105:1079-83. [HTTPS://DOI.ORG/10.1016/J.OTSR.2019.04.026](https://doi.org/10.1016/j.otsr.2019.04.026).
- [23] JACQUET C, GULAGACI F, SCHMIDT A, PENDSE A, PARRATTE S, OLLIVIER M.. OPENING WEDGE HIGH TIBIAL OSTEOTOMY ALLOWS BETTER OUTCOMES THAN UNICOMPARTMENTAL KNEE ARTHROPLASTY IN PATIENTS PRACTICING IMPACT SPORTS BEFORE THE ONSET OF ARTHRITIC SYMPTOMS. KNEE SURG SPORTS TRAUMATOL ARTHROSC 2020 DOI: 10.1007/s00167-020-05857-1

# THE “FUNCTIONAL KNEE PHENOTYPE CONCEPT” AND ITS IMPACT ON THE CONTROVERSY OF PROPER FRONTAL ALIGNMENT IN TKA

Silvan Hess<sup>1,2,3</sup>, Emma-Louise Robertson<sup>2</sup>, Lukas B. Moser<sup>4</sup>, Michael T. Hirschmann<sup>2,5</sup>

1-Department of Surgery and Traumatology, Kantonsspital Graubünden, 7000 Chur, Switzerland  
 2-Department of Surgery and Traumatology, Kantonsspital Baselland (Bruderholz, Liestal, Laufen), 4101 Bruderholz, Switzerland  
 3-University of Bern, 3012 Bern, Switzerland  
 4-Universitätsklinikum Krems, 3500 Krems, Austria  
 5-University of Basel, 4001 Basel, Switzerland

## INTRODUCTION

Despite the general acceptance of TKA as the treatment of choice in end stage osteoarthritis, the best method of performing a TKA is still under debate. The optimal implant alignment is only one topic among many others, but it has increasingly gained attention for many knee surgeons (1). Currently there are at least five different alignment concepts promoted, which have led to some confusion among knee surgeons as differences between these concepts are often not

understood well enough (2) (Figure 1). Currently there is no evidence that one of these concepts will be more beneficial for the patient with regards to the functional outcome or long-term survival.

Recent papers proved that there is a very wide anatomical variation in the deformity of the knee in the young non-osteoarthritic knees planned for TKA (3–8). The concept of “deformity analysis” to investigate this broad variation has been described by D. Paley more than 20 years ago for osteotomies (9). However, this simple analysis on full leg films has unfortunately not been widely used by knee surgeons

for their TKA planning (9). On the other hand, this deformity analysis builds the foundation for computer navigation, patient specific cutting blocks and recently robotic surgery (10).

In this paper the different alignment concepts for TKA will be described and the possible Pros and Cons presented. The new functional knee phenotype concept will be explained and its impact on the frontal alignment controversy will be discussed.

## MECHANICAL ALIGNMENT

For decades the mechanical alignment concept introduced by Michael Freeman has been the “gold standard” for TKA (11). Based on old biomechanical and clinical studies, a mechanical neutrally aligned lower limb with joint lines perpendicular to the mechanical axes has been promoted as the goal for the last 40 years (12). Excellent long-term implant survivorship and a relatively high patient satisfaction rate have been achieved with this

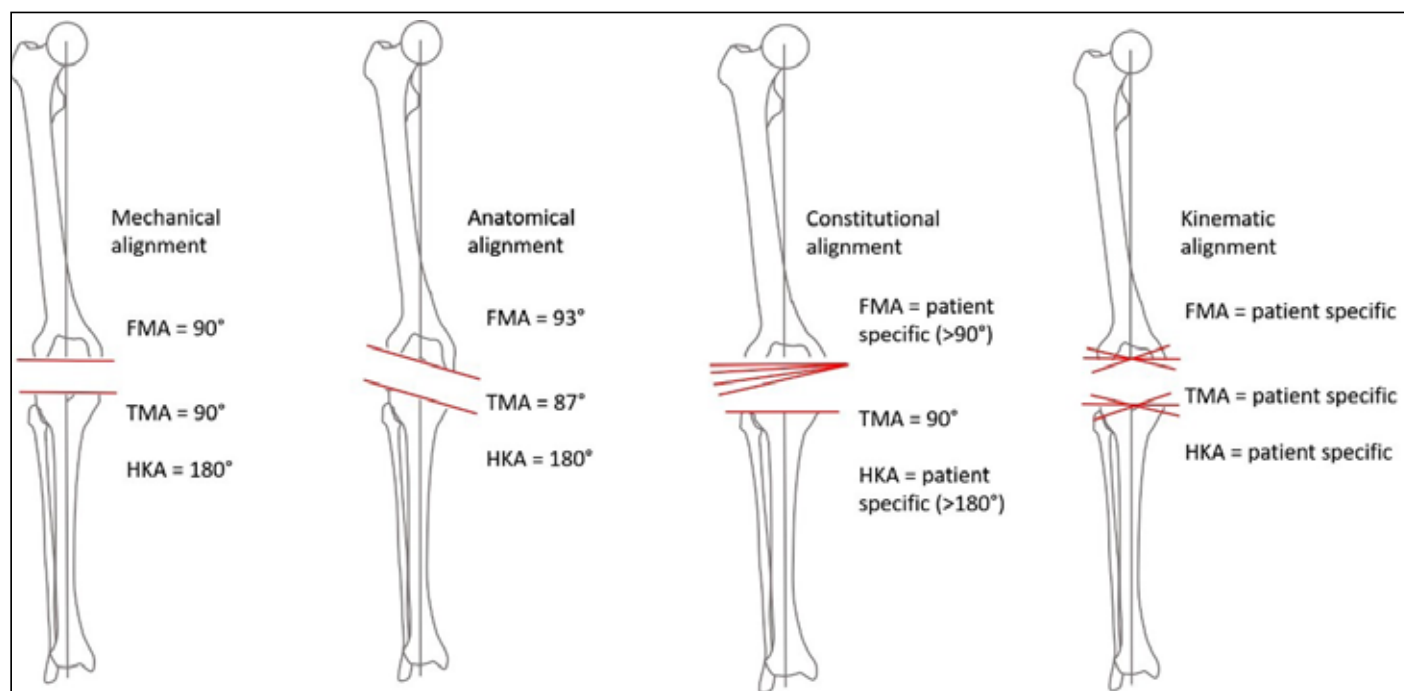




Figure 1: Different Alignment Options for TKA




# Better Cuts.



Ultra-fine A/P adjustment anywhere from -2mm to +2mm promotes component positioning accuracy.



Facilitates high-precision sizing and cuts for all 13 of United's femoral components.



Permits external rotation from 3° to 7°.



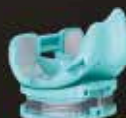## U2™ Knee All-in-One Block - Sizer and AP Cutting jig

- Supports both anterior and posterior referencing
- Guides all 13 sizes of anterior and posterior femoral cuts in one block
- Innovative, all-in-one design reduces the need to stock and sterilize multiple instruments

from **6** trays to **1.5** trays

### Reduce table clutter, mitigate infection risk.

When used together, the U2™ Knee All-in-One Block and Modular Disposable Trial can reduce instrument tray count from 6 to 1.5.



UNITED  
ORTHOPEDIC®

Since 1993, United Orthopedic has had the privilege of supplying world class orthopedic joint replacements, till now, had helped in 38 countries over 250 thousand suffering patients gain back their mobility and quality of life.

### United Orthopedic Corporation EU

Avenue Général Guisan 60A, 1009 Pully- Switzerland  
Phone +41 21 634 70 70 • contact@uoc-swiss.ch

[eu.unitedorthopedic.com](http://eu.unitedorthopedic.com)

concept, which is why it still remains the alignment concept of choice for most surgeons (1). However, the superiority of the mechanical alignment concept has been repeatedly questioned over the last decades. Parratte et al. challenged the long-held dogma of “malaligned” TKA being associated with decreased durability (13). Furthermore, since its introduction surgeons recognized that this systematic approach leads to a significant alteration of the patient’s native anatomy, which results in new artificial biomechanics and the need for some soft tissue releases in most of the cases. Opponents of this concept claim that this has a negative impact on the functionality and kinematics and might be the major cause for the 20 % unsatisfied TKA patients (2,14).

## ANATOMICAL ALIGNMENT

In 1980s, Hungerford and Krackow already proposed the anatomical alignment concept, which aims to improve functionality by recreating a more native joint line orientation (15). An oblique joint line orientation (frontal bone cuts femur 3° valgus and tibia 3° varus) which better mimics the average native joint line orientation was promoted as goal. This was the first alternative alignment concept and implicated a better load distribution on the tibial component, better patellar kinematics and reduced risk for lateral ligament stress (16,17). Despite these theoretical advantages, clinical results did not show any benefits and concerns regarding the risk of excessive varus tibia alignment and increased wear prevented the wide spread of this concept. Subsequently, the mechanical alignment concept remained the gold standard until today.

## CONSTITUTIONAL ALIGNMENT

Bellemans et al. highlighted the fact that most people do not have a straight lower limb. In his classical paper, they showed that in a young and healthy population nearly 36% of the male and 17% of the female had a constitutional varus knee malalignment (represented by a hip-knee-ankle angle (HKA) < 177°) (18). Consequently, they questioned the tenet to correct all patients to neutral alignment, which will need unnecessary soft tissue releases and change their natural biomechanics. With this new approach they introduced the concept of “constitutional alignment”, which will leave varus and valgus knees in some residual under correction. They proposed to perform under correction at the femur and place the tibia in 90° to the mechanical axis. This will allow a more patient specific alignment and to perform no releases in non-severe and less releases in more deformed knees. The same research group retrospectively assessed clinical and radiological outcome of 143 patients with medial knee OA and a preoperative varus alignment (19). At a mean follow up of 7.2 years, patients with a mild postoperative varus showed significantly better KSS and WOMAC score than patients with a severe varus or neutral postoperative alignment. The mal-aligned group did not have an inferior survivorship compared to the well aligned TKA group. However, none of patients needed revision during this follow up midterm. Opponents of this concept claim that there are conflicting outcomes published and there is no evidence in RCT studies, that constitutional alignment will have a benefit for TKA patients compared to mechanical alignment. Furthermore, the limit of under correction is not clear and the alignment, with correction at the femur only is not a natural one.

## KINEMATICAL ALIGNMENT

The biomechanical basis for TKA goes back to Hollister et al, who published the kinematic axis for the knee already in 1993 (20). Kinematic alignment (KA) for TKA was already introduced by Howell in combination with patient specific cutting blocks in 2008 (21). The concept is pure cartilage restoration without corrections of bony deformities in any of the three planes. The target is to restore the pre-arthritic alignment and kinematics of the knee to allow more natural biomechanics, no releases and better function (14). The KA concept is promoted mainly by Howell and his group. They claim no limitations for deformities, no intraoperative problems, not more complications, better functional outcome and long-term survival up to 10 years comparable to mechanical alignment (22). Many KA surgeons do not follow the pure KA concept and perform restricted KA by selecting patients with non-severe deformities and allow limited residual malalignment after TKA only (23).

Conflicting results have been published in several studies reporting better outcomes for KA in comparison to mechanical alignment (14,22,24), while others did not find any differences (25–27). So far long-term data for KA are only available from one research group (22). Opponents of this concept claim that the clinical benefit is not proven, patient selection is still not clear, the surgical technique to adapt the tibia bone cuts to the soft tissue frame is difficult and the risk for varus malalignment especially at the tibia is underestimated by KA surgeons (28–30).

## FUNCTIONAL KNEE PHENOTYPE CONCEPT

Breaking long-held dogmas can cause a certain amount of uncertainty, but it can also be seen as an opportunity to reassess our knowledge about alignment and build an evidence-based foundation for a more patient-specific approach to TKA.

The recently introduced functional “knee phenotype concept” (KPC) might play an important role in this movement. The concept is based on the alignment analysis of a young non-OA population of 308 knees and enables a new and comprehensive way to evaluate the frontal knee alignment and implant orientation (3–5). The concept was further validated using data on osteoarthritic knees. Until now, the discussion regarding the optimal frontal alignment has been focused on the influence of the overall alignment or a certain alignment concept on the clinical outcome only. However, the analysis of the coronal alignment of a young non-OA population showed that is approach might be short-sighted (3–5). Not only the overall lower limb alignment (represented by the HKA) is very variable but also the orientation of the femoral and tibial joint line represented by the femoral mechanical angle (FMA) and tibial mechanical angle (TMA) (Figure 2) (5). Others have previously highlighted the variability of the anatomy in OA and native knees, but data on native knees has been limited and investigations have mainly been restricted to mean values or ranges of each angle separately (18,31,32). It is important to understand that when assessing and comparing only mean values or ranges of one angle independently, critical information is lost.

A completely new picture emerges when the KPC is used to analyse the individual alignment based on phenotypes. A phenotype thereby either represents a coronal alignment variation of the femur (femoral phenotype), the tibia (tibial phenotype) or the

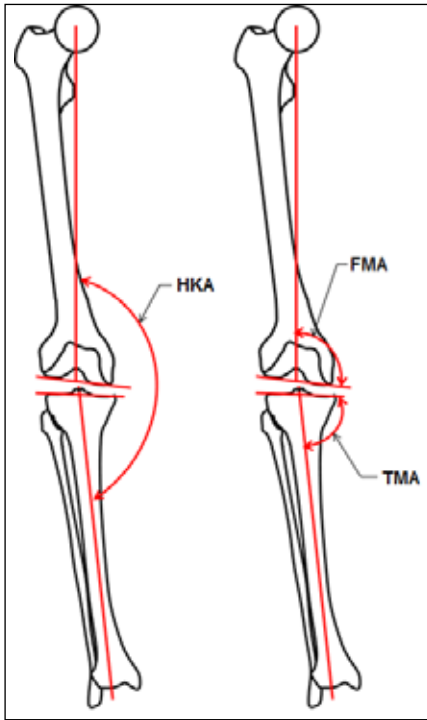


Figure 2: Key alignment angles in frontal plane Hip-knee-ankle (HKA), femur mechanical angle (FMA) and tibia mechanical angle (TPA)

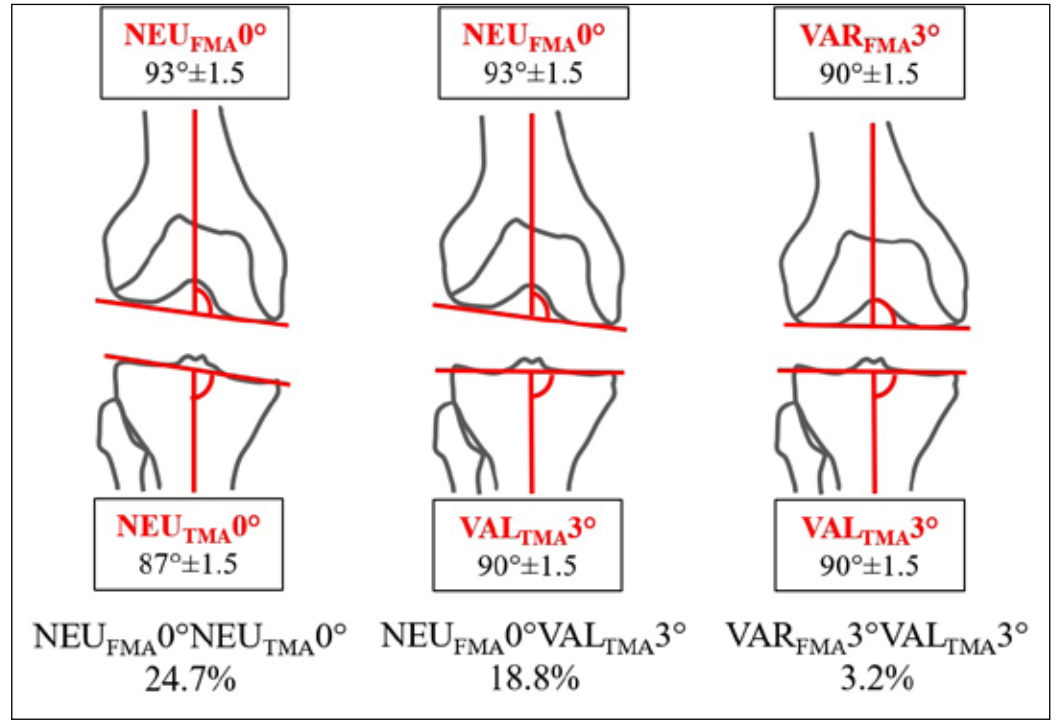


Figure 3: The three most common knee phenotypes and the prevalence in the young non-OA population.

overall lower limb (limb phenotype). Each alignment variation is based on specific angles (FMA for the femur, TMA for the tibia and HKA for the overall limb) and each phenotype represents a range of  $\pm 1.5^\circ$  from a phenotype specific mean value. The name of phenotypes thereby contains of three parts. Part 1 defines the direction of deviation (NEU, VAR, VAL) from the overall mean value of the angle, part two defines the phenotype specific angle (second subscripted part: HKA, FMA, or TMA) and part 3 the average deviation from the mean values ( $0^\circ$ ,  $3^\circ$  and  $6^\circ$ ) (Fig 3).

For example, the most common femoral alignment variation (i.e. femoral phenotype) was NEUFMA $0^\circ$ , which means that most patients had a femoral mechanical angle within the range of  $93^\circ \pm 1.5$ . The innovative part of the functional knee phenotype is the combination of the different phenotypes into knee phenotypes (combination of femoral and tibial phenotypes) and functional knee phenotypes (combination of all three phenotypes). Combining femoral and tibial phenotypes revealed that the most common knee phenotype with 24,7% matched the joint line orientation of the anatomical alignment concept (FMA

Category	Deviation	Name	Mean value	Range
Limb phenotypes (Hip-knee-ankle angle; HKA)	VAR <sub>HKA</sub>	VARHKA $9^\circ$	171°	169.5°<HKA<172.5°
		VARHKA $6^\circ$	174°	172.5°<HKA<175.5°
		VARHKA $3^\circ$	177°	175.5°<HKA<178.5°
	NEU <sub>HKA</sub>	NEUHKA $0^\circ$	180°	178.5°<HKA<181.5°
	VAL <sub>HKA</sub>	VALHKA $3^\circ$	183°	181.5°<HKA<184.5°
		VALHKA $6^\circ$	186°	184.5°<HKA<187.5°
VALHKA $9^\circ$		189°	187.5°<HKA<190.5°	
Femoral phenotypes (Femoral mechanical angle; FMA)	VAR <sub>FMA</sub>	VARFMA $6^\circ$	87°	85.5°<FMA<88.5°
		VARFMA $3^\circ$	90°	88.5°<FMA<91.5°
	NEU <sub>FMA</sub>	NEUFMA $0^\circ$	93°	91.5°<FMA<94.5°
	VAL <sub>FMA</sub>	VALFMA $3^\circ$	96°	94.5°<FMA<97.5°
		VALFMA $6^\circ$	99°	97.5°<FMA<100.5°
	Tibial phenotypes (Tibial mechanical angle; TMA)	VAR <sub>TMA</sub>	VARTMA $6^\circ$	81°
VARTMA $3^\circ$			84°	82.5°<TMA<85.5°
NEU <sub>TMA</sub>		NEUTMA $0^\circ$	87°	85.5°<TMA<88.5°
VAL <sub>TMA</sub>		VALTMA $3^\circ$	90°	88.5°<TMA<91.5°
		VALTMA $6^\circ$	93°	91.5°<TMA<94.5°

Table 1: The definitions for all coronal phenotypes

=  $93^\circ \pm 1.5$ , TMA =  $87^\circ \pm 1.5$  = NEUFMA $0^\circ$ NEUTMA $0^\circ$ ). A substantial part of the population (18.8%) had a normal femur (FMA =  $93^\circ \pm 1.5$ ; NEUFMA $0^\circ$ ) and a slight valgus tibia (TMA  $90^\circ \pm 1.5$  = VALTMA $3^\circ$ ). While mechanical joint line orientation (FMA =  $90^\circ \pm 1.5$ , TMA =  $90^\circ \pm 1.5$  = VARFMA $3^\circ$ VALTMA $3^\circ$ ) on the other hand was found in less than 4% of the population.

The most interesting part of the functional KPC is the combination of all three phenotypes (limb, femur and tibia). This showed that the orientation of the femoral and tibial joint lines is much more variable within a limb phenotype (e.g. a population of patient with a similar HKA) than expected. In the population of patients with a neutral limb phenotype (HKA within the range of  $180^\circ \pm 1.5$ ; limb phenotype NEUHKA $0^\circ$ )

nine different combinations of femoral and tibial joint line orientation were found (i.e. knee phenotypes). Similarly, in the population with a slight varus overall lower limb alignment (HKA within the range of  $177^\circ \pm 1.5$ ; limb phenotype VARHKA $3^\circ$ ), ten different knee phenotypes were found (4). Table 1 summarizes the distribution of the functional knee phenotypes in young and non-osteoarthritic knees.

By enabling a different view on the alignment, the functional knee system could potentially have a significant impact on the discussion surrounding the optimal TKA alignment. Taking the example from above and linking it to TKA is a simple way to illustrate the advantage of the functional knee phenotype concept. If patients with a neutrally aligned limb have nine differently orientated femoral and tibial joint lines, why should a mechanical alignment be the optimal alignment for all of these patients?

Moreover, if the joint line orientation differs among neutral aligned patients, the impact of different alignment concept might vary significantly. Figure 4 shows the two most common phenotypes and the impact of the two alignment concepts in terms of change in joint line orientation. In the first case with NEUHKA0°NEUFMA0°NEUTMA0° (HKA: 180° ±1.5; FMA: 93° ±1.5; TMA: 87° ±1.5) when mechanical alignment concept is followed the orientation of tibial and femoral joint lines are changed and when performing the anatomical alignment concept, no

change is needed for both joint lines. In the second case with NEUHKA0°NEUFMA0°VALTMA3° (HKA: 180° ±1.5; FMA: 93° ±1.5, TMA: 90° ±1.5) both concepts result in a change of 3° but either only in the femur (mechanical alignment concept) or only in the tibia (anatomical alignment concept).

It can also be seen that depending on the knee phenotype of a patient and the utilized alignment concept, collateral ligament offsets and soft tissue envelope strains are altered in a different way. This might have the biggest impact on knee function after TKA and may partly explain why studies assessing the connection between change in alignment (pre-to post) and clinical outcome reported conflicting results. In fact, a potential additional advantage of the functional knee phenotype concept might be that patients with a similar alignment can be clustered together. This limits the complexity of the system and acknowledges the fact that small differences or changes to the alignment might not affect the clinical outcome.

What could be the specific consequences of the KPC on our everyday clinical work? Until now, the practical impact of the functional knee system is limited because clinical studies using the system are missing. Nevertheless, the possible applications of the system seem to be straight forward. For example, based on previous studies (19), we know that patients with a preoperative varus alignment might benefit from a postoperative alignment, which is still in slight varus. The second most common phenotypes in the study by Hirschmann and colleagues was VARHKA3°VARFMA3°NEUTMA0° (HKA 177°±1.5; FMA: 90°±1.5; TMA: 87°±1.5). It seems to be reasonable that for this type of OA patients (mainly females), the optimal prosthesis orientation might be this phenotype. Continuing this thought, based on further research, it might be possible to propose the use of a certain phenotype alignment concept or alignment variation (i.e. functional knee phenotype) for a specific patient or rather groups of patients with a specific functional knee phenotype. The functional knee phenotype concept therefore

could be a useful tool for a more patient-specific approach in TKA surgery.

However, it seems important to note that this approach does not favour or exclude the use of one specific alignment concept. It should instead foster an open and evidence-based discussion about the benefits and risk associated with the use of an alignment concept for a specific group of patients. It is obvious that the functional knee phenotype system can be seen as work in progress. An assessment not only of the frontal, but also of the sagittal, rotational and femoral-patellar alignment seems to be essential. The most important point will be to adapt the functional KPC to osteoarthritic knees scheduled for TKA, since the deformities are significantly different to the deformities used in the previous study (Hess, KSSTA 2019, Springer, KSSTA 2019). Lastly, clinical studies will have to show a clear benefit for the patient.

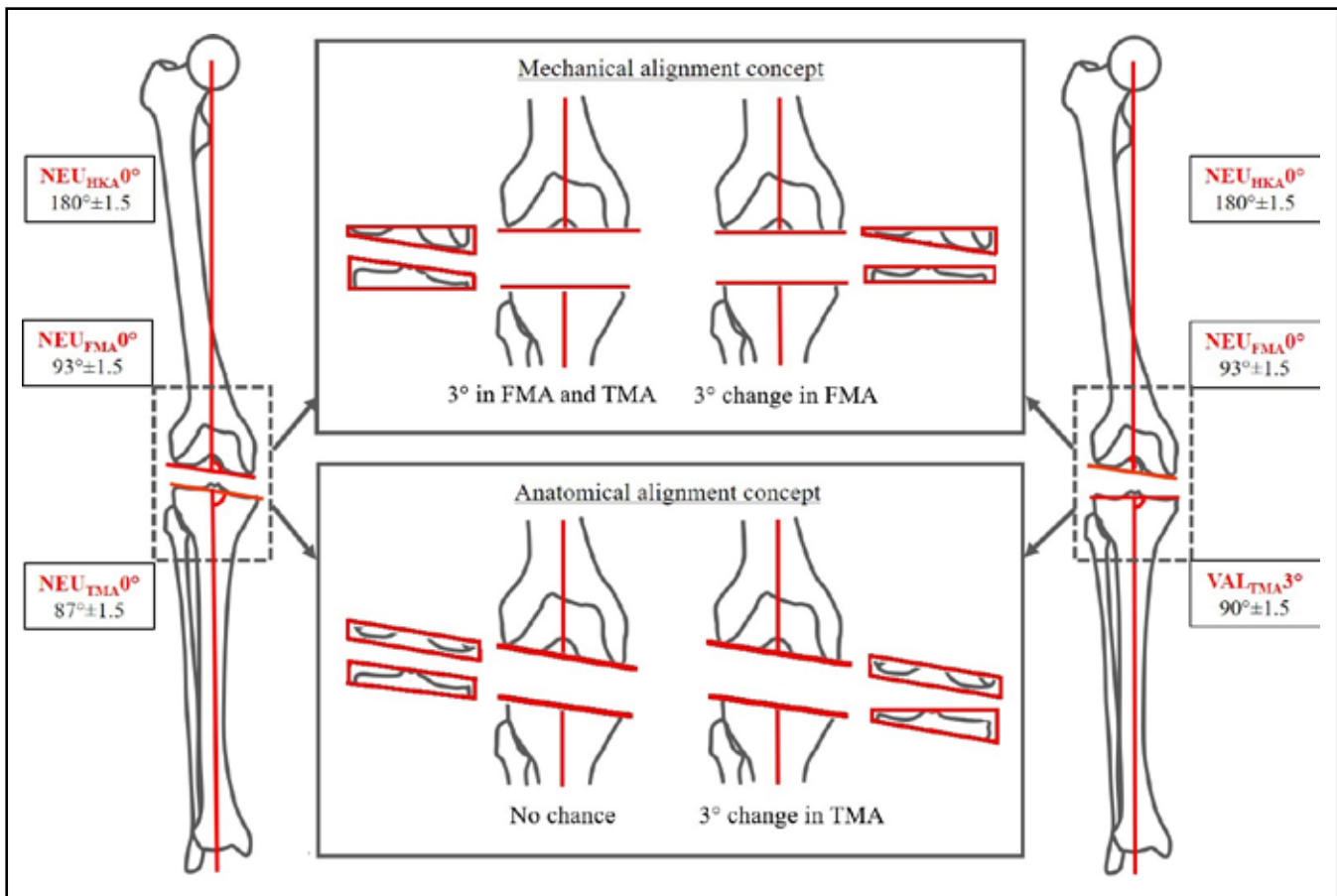


Figure 4: The impact of the mechanical and anatomical alignment on the two most common functional knee phenotypes.

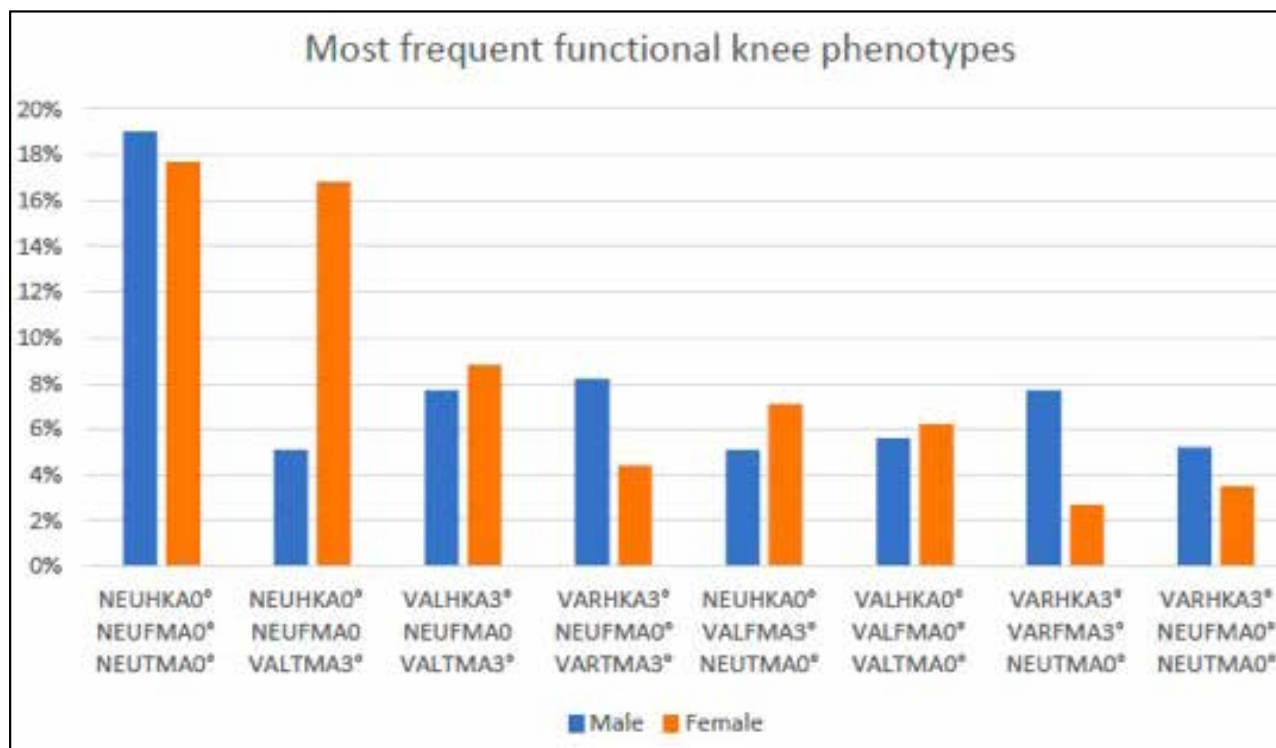


Table 2: The most common knee phenotypes for females and males

References

- Hungerford DS, Krackow KA. Total Joint Arthroplasty of the Knee. Clin Orthop Relat Res 1985;192:23–33.
- Ghosh KM, Merican AM, Iranpour-Boroujeni F, Deehan DJ, Amis AA. Length change patterns of the extensor retinaculum and the effect of total knee replacement. Journal of Orthopaedic Research 2009;27:865–870.
- Klatt BA, Goyal N, Austin MS, Hozack WJ. Custom-Fit Total Knee Arthroplasty (OtisKnee) Results in Malalignment. The Journal of Arthroplasty 2008;23:26–29.
- Parratte S, Pagnano M, Trousdale R, Berry D. Effect of Postoperative Mechanical Axis Alignment on the Fifteen-Year Survival of Modern, Cemented Total Knee Replacements. The Journal of Bone & Joint Surgery 2010;92:2143–2149.
- Bellemans J, Colyn W, Vandenneucker H, Victor J. The Chitranjan Ranawat award: is neutral mechanical alignment normal for all patients? The concept of constitutional varus. Clin Orthop Relat Res 2012;470:45–53.
- Vanlommel L, Vanlommel J, Claes S, Bellemans J. Slight undercorrection following total knee arthroplasty results in superior clinical outcomes in varus knees. Knee Surg Sports Traumatol Arthrosc 2013;21:2325–2330.
- Howell SM, Hull ML. Kinematic Alignment in Total Knee Arthroplasty. In: Insall and Scott Surgery of the Knee. Elsevier; 2012:1255–1268.
- Dossett HG, Swartz GJ, Estrada NA, LeFevre GW, Kwasman BG. Kinematically versus mechanically aligned total knee arthroplasty. Orthopedics 2012;35:e160–169.
- Howell SM, Papadopoulos S, Kuznik KT, Hull ML. Accurate alignment and high function after kinematically aligned TKA performed with generic instruments. Knee Surg Sports Traumatol Arthrosc 2013;21:2271–2280. doi.org/10.1007/s00167-013-2621-x.
- Howell SM, Shelton TJ, Hull ML. Implant Survival and Function Ten Years After Kinematically Aligned Total Knee Arthroplasty. J Arthroplasty 2018;33:3678–3684.
- McEwen PJ, Dlaska CE, Jovanovic IA, Doma K, Brandon BJ. Computer-Assisted Kinematic and Mechanical Axis Total Knee Arthroplasty: A Prospective Randomized Controlled Trial of Bilateral Simultaneous Surgery. The Journal of Arthroplasty 2019;0.
- Xu J, Cao JY, Luong JK, Negus JJ. Kinematic versus mechanical alignment for primary total knee replacement: A systematic review and meta-analysis. Journal of Orthopaedics 2019;16:151–157.
- Young SW, Walker ML, Bayan A, Briant-Evans T, Pavlou P, Farrington B, The Chitranjan S. Ranawat Award : No Difference in 2-year Functional Outcomes Using Kinematic versus Mechanical Alignment in TKA: A Randomized Controlled Clinical Trial. Clin Orthop Relat Res 2017;475:9–20.
- Hirschmann MT, Becker R, Tandogan R, Vendittoli P-A, Howell S. Alignment in TKA: what has been clear is not anymore! Knee Surg Sports Traumatol Arthrosc 2019;27:2037–2039. doi.org/10.1007/s00167-019-05558-4.
- Hirschmann MT, Hess S, Behrend H, Amsler F, Leclercq V, Moser LB. Phenotyping of hip-knee-ankle angle in young non-osteoarthritic knees provides better understanding of native alignment variability. Knee Surg Sports Traumatol Arthrosc 2019;27:1378–1384.
- Hirschmann MT, Moser LB, Amsler F, Behrend H, Leclercq V, Hess S. Phenotyping the knee in young non-osteoarthritic knees shows a wide distribution of femoral and tibial coronal alignment. Knee Surg Sports Traumatol Arthrosc 2019;27:1385–1393. doi.org/10.1007/s00167-019-05508-0
- Hirschmann MT, Moser LB, Amsler F, Behrend H, Leclercq V, Hess S. Functional knee phenotypes: a novel classification for phenotyping the coronal lower limb alignment based on the native alignment in young non-osteoarthritic patients. Knee Surg Sports Traumatol Arthrosc 2019;27:1394–1402.
- Cooke DT, Harrison L, Khan B, Scudamore A, Chaudhary AM. Analysis of limb alignment in the pathogenesis of osteoarthritis: a comparison of Saudi Arabian and Canadian cases. Rheumatol Int 2002;22:160–164. doi.org/10.1007/s00296-002-0218-7.
- Thienpont E, Schwab P-E, Paternostre F, Koch P. Rotational alignment of the distal femur: anthropometric measurements with CT-based patient-specific instruments planning show high variability of the posterior condylar angle. Knee Surg Sports Traumatol Arthrosc 2014;22:2995–3002. doi.org/10.1007/s00167-014-3086-2.
- Lee H-J, Lim J-W, Lee D-H, Kim D-H, Park Y-B. Slight under-correction using individualized intentional varus femoral cutting leads to favorable outcomes in patients with lateral femoral bowing and varus knee. Knee Surg Sports Traumatol Arthrosc 2019. /doi.org/10.1007/s00167-019-05577-1

# A DIAGNOSTIC ALGORITHM FOR ACUTE SYNDESMOTIC INJURIES OR "HIGH ANKLE SPRAINS": HISTORY, PHYSICAL FINDINGS AND IMAGING

S.A. Stufkens

Orthopaedic Surgeon, Amsterdam University Medical Centers,  
Location AMC, Meibergdreef 9, 1105 AZ Amsterdam, The Netherlands

email: [s.a.stufkens@amsterdamumc.nl](mailto:s.a.stufkens@amsterdamumc.nl)

## INTRODUCTION

The syndesmotous complex plays an important role in the stability of the talocrural joint. Understanding the anatomy of the structures is mandatory for interpretation of clinical symptoms, radiographs, CT, MRI and ankle arthroscopy. [1]

The distal tibiofibular syndesmosis includes four main structures. The anterior-inferior tibiofibular ligament (AiTFL) connects the anterolateral tubercle of the distal tibia to the anterior tubercle of the distal fibula. An accessory anterior-inferior tibiofibular ligament, also called Bassett's ligament, is described in the literature. [2] (Figure 1) The posterior-inferior tibiofibular ligament (PiTFL) connects the posterior tubercle of the distal tibia to the posterior part of the distal fibula. The interosseous ligament (IOL) is a distal thickened continuation of the interosseous membrane. The interosseous ligament (IOL) lies 0.5 to 2 cm above the joint line. The area underneath the interosseous ligament is generally filled with the synovial plica from the tibiotalar joint. [3, 4] The inferior transverse ligament (ITL) forms the most distal aspect of the tibiotalar articulation and functions as a labrum. The PiTFL, like the AiTFL, consists of multiple collagen bundles and fat. Its most distal fibres sometimes seem continuous with the transverse ligament. (Figure 2) [3]

The syndesmotous ligaments connect the distal fibula tightly to the distal tibia. The physiological envelope of motion of the syndesmotous ligamentous complex is approximately 1mm in translation and 4 degrees of rotation. [5-7] The main stabilizer of the talus underneath the tibia however is the deltoid ligament. [8-10] Syndesmotous injuries in combination with deltoid ligament injuries render the ankle joint highly unstable. [11]

Several mechanisms of syndesmotous injury have been reported. Dorsiflexion and external rotation is most commonly described. Syndesmotous injuries frequently occur in athletes, mostly in collision sports. Fritschy noted syndesmotous injuries in skiing with the introduction of more firm skiing boots extending above the ankle. [12] He observed syndesmotous injuries when the foot and ankle experienced forced external rotation within the ski boot. Also in the classical work of "ligamentous ankle fractures", Lauge-Hansen reported the external rotation of the foot causing AiTFL ruptures. [13]

The incidence of syndesmotous injuries is thought to be 0.5% of all ankle sprains without fracture and 13% of all ankle fractures. Isolated syndesmotous injuries are more difficult to diagnose than those that result from ankle fractures. There is a lack of consensus on diagnostic criteria for isolated acute syndesmotous injuries. The low accuracy of several physical and radiological tests may predispose to late or missed diagnosis.

Inappropriate (under-)treatment might ultimately lead to chronic syndesmotous insufficiency, chronic ankle pain, and eventually osteoarthritis of the ankle joint. [14] In this paper the history, clinical examinations, imaging modalities and therapeutic options will be described using an algorithmic approach.

## HISTORY

The physician should be aware of the patient that has a higher a-priori chance of having a syndesmotous injury. A young athlete performing contact/collision sports, having suffered a pivoting trauma with the ankle joint is suspected for a syndesmotous injury. Patients with isolated syndesmotous injuries, or so-called high ankle sprains, generally present with acute ankle instability, pain, and functional deficits. [15] The history should include the mechanism of injury, previous injuries or surgical procedures, and symptoms of instability.

## PHYSICAL EXAMINATION

There are 6 different clinical tests mentioned in the literature (Table 1), which will be described in more detail. According to a recent review three of them seem to be the most accurate ones marked with\* [16].

Table 1 – Diagnostic Tests

- Palpation pain test\*
- External rotation test\*
- Squeeze test\*
- Cotton test
- Fibula translation test
- Stabilizing test

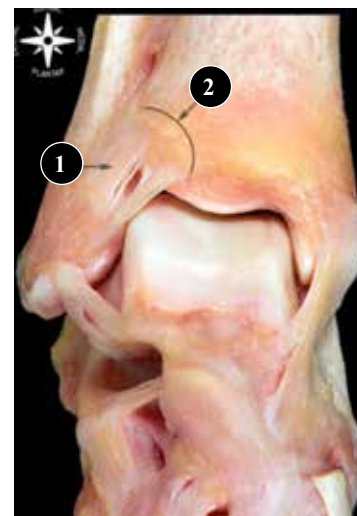


Figure 1: Ankle joint with AiTFL  
① AiTFL, the distal fascicle is also known as Bassett's ligament; ② foot-print of AiTFL on the tibia

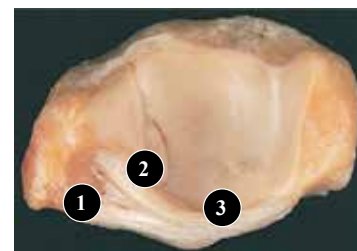


Figure 2: Ankle joint with posterior syndesmotous ligaments  
① PiTFL; ② transverse ligament; ③ continuation of transverse ligament functions as a "labrum" like extension of the posterior malleolus



**Fashion Meets Science**

# 19<sup>th</sup> **ESSKA CONGRESS** **VIRTUAL!** 11-15 May 2021

No flights, no hotels, no need to take time off work, simply **top-quality science** delivered directly to your living room, study, bed, garden, terrace, the choice is yours!



**Register Now**

[www.esska-congress.org/registration](http://www.esska-congress.org/registration)



**450+**  
experts /  
speakers



**130+**  
scientific  
hours



**150+**  
top class  
sessions



**UEMS CME**  
accredited  
event



**405 videos**  
on demand, available during  
and after the congress

## Scientific Programme Overview now online

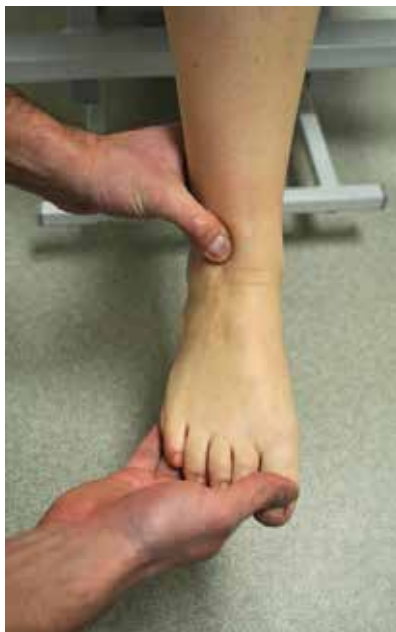DAY/ CHANNEL	Channel 1 LIVE	Channel 2 On demand	Channel 3 On demand	Channel 4 On demand	Channel 5 On demand	Channel 6 - Free Papers and E-Posters Accessible during the whole time of the congress				Industry Channel LIVE	
Tuesday 11 May	Industry Symposia 14:00-15:00					Free Papers ACL	Free Papers Cartilage & Meniscus	Free Papers Degenerative Knee (I)	Free Papers Shoulder, Elbow and Sports	Free Papers Hip and Ankle	
	Industry Symposia 15:00-16:00										
	Industry Symposia 16:00-17:00										
	Resident's Days 16:45-21:00										
	Industry Symposia 21:00-22:00										
Wednesday 12 May	Highlight and Keynote Lectures 18:00-22:00	All about ACL 9:00-18:00	All about Shoulder surgery 9:00-18:00	All about Foot & Ankle 9:00-18:00	All about Hip Arthroscopy 9:00-18:00						Programme provided by Industry Partners 9:30-17:00
Thursday 13 May	Industry Symposia 17:00-18:00	All About Meniscus 9:00-18:00	All about Rotator Cuff Repair 9:00-18:00	Hip Arthroscopy and Ortho- biologics 9:00-18:00	All about Sports 9:00-18:00						Programme provided by Industry Partners 9:30-17:00
	Highlight and Keynote Lectures 18:00-22:00										
Friday 14 May	Industry Symposia 17:00-18:00	All about Complex Knee instability 9:00-18:00	All about Degenerative Knee (II) 9:00-18:00	All about Cartilage 9:00-18:00	All about Shoulder & Elbow 9:00-18:00						Programme provided by Industry Partners 9:30-17:00
	Highlight and Keynote Lectures 18:00-22:00										
Saturday 15 May	Industry Symposia 8:30-9:30	Partner Societies 9:30-13:00	All about Degenerative Knee (III) 9:30-13:00	All bout Patellofem- oral Instability 9:30-13:00							Programme provided by Industry Partners 12:30-18:00
	Highlight and Keynote Lectures 9:30-13:00										

Follow us!

[www.esska-congress.org](http://www.esska-congress.org)

### Palpation pain test (Figure 3)

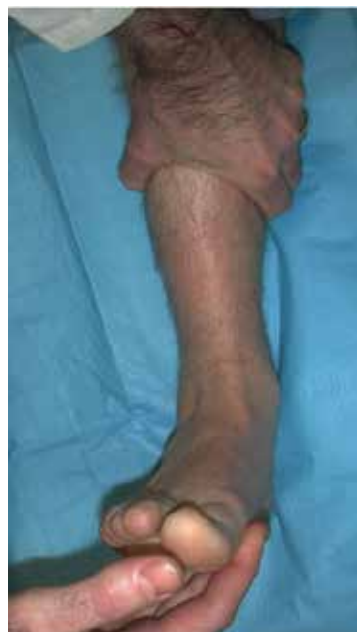The patient typically presents with limited swelling but marked pain over the syndesmotic ligaments. In most cases only the AiTFL is ruptured, therefore the pain is located on the anterior side, more than on the posterior side of the ankle joint.



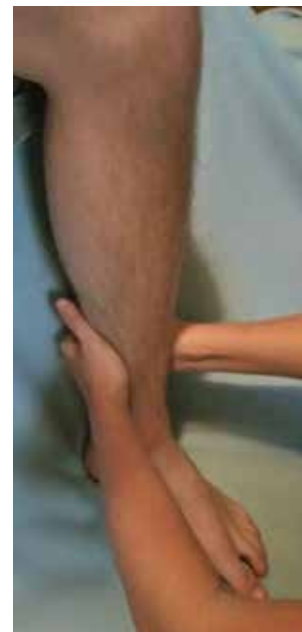**Figure 3: Palpation pain test**  
Physical examination where the AiTFL is palpated. A positive test is when the anterior syndesmosis is tender on palpation.

### External rotation stress test (Figure 4)

The external rotation stress test consists of stabilization the leg with the knee in 90 degrees of flexion, followed by manual external rotation of the foot. A positive result is when the patient reports pain over the syndesmosis. [17-19]



**Figure 4: External rotation test**  
Physical examination where the foot is rotated externally with regard to the lower leg. A positive test is when the patient reports pain in the syndesmotic area. The test is validated with the knee in 90 degrees of flexion (with the patient sitting).



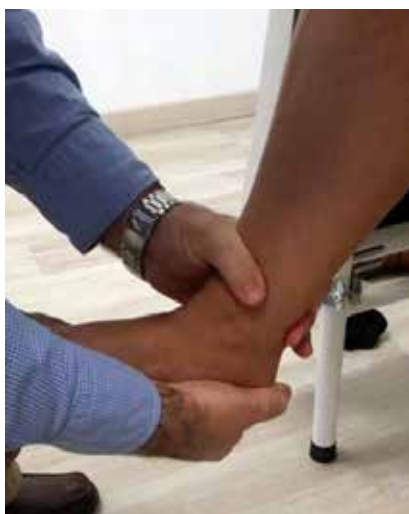**Figure 5: Squeeze test**  
Physical examination where the calf is squeezed midway. During the test the distal syndesmotic ligaments widens. A positive test is when the patient reports pain in the syndesmotic area during this test.

### Squeeze test (Figure 5)

The squeeze test consists of applying compression of the proximal part of the fibula to the tibia, separating the two bones distally. A positive result is when the patient reports pain over the syndesmosis. [19, 20]

### Cotton test (Figure 6)

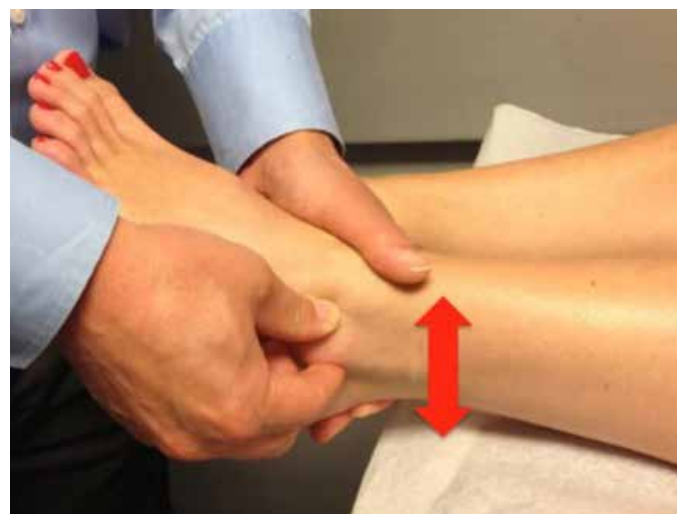The Cotton test is performed by translating the talus within the ankle mortise from medial to lateral. Increased translation or pain may suggest syndesmosis involvement, as well as a deltoid (medial) ligament injury.



**Figure 6: Cotton test**  
Examination where the heel is fixated and pushed laterally with regard to the lower leg. In this manner the talus is lateralized in the mortise. An insufficient syndesmosis (and deltoid ligament) allow the talus to lateralize and apply stress on the syndesmosis. A positive test is when the patient reports pain in the syndesmotic area during the test.

### Fibula translation test (Figure 7)

With the fibula translation (drawer) test, the examiner attempts to translate the fibula from anterior to posterior. In the normal ankle, there is a firm end point and little movement. Increased translation relative to the contralateral side and pain indicate a positive test result.



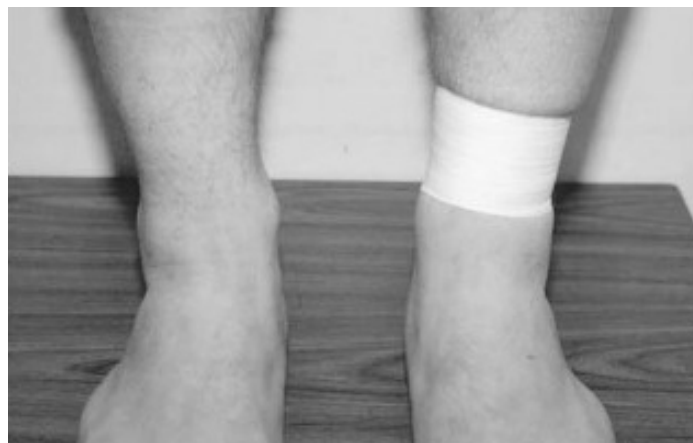**Figure 7: Fibula translation test**  
Physical examination where the fibula is pushed posteriorly. A positive test is when there is marked movement of the fibula relative to the tibia.

### Stabilization test (Figure 8)

Amendola has described the "stabilization test," [21] which can be useful to confirm diagnosis during the subacute or chronic phase of injury once acute swelling and pain have subsided. This test is performed by tightly applying several layers of 1.5-in athletic tape just above the ankle joint to stabilize the distal syndesmosis. The patient is then asked to stand, walk, and perform a toe raise and jump. The test result is positive if these

### Figure 8: Stabilization test

Physical examination where a sports tape is applied at the level of the syndesmosis. This "ring tape" or "syndesmosis tape" stabilizes the distal tibiofibular joint. A positive test is when the patient notices a marked relief of pain after application of the tape, during activities such as walking, jumping, etc.





maneuvers are less painful after taping.

### Accuracy of different clinical tests

Biomechanical evaluation of the four most common clinical tests showed that accurate prediction of the degree of mechanical injury is not possible with clinical testing alone. [22]

Diagnostic accuracy of several physical tests was reviewed systematically. [23] Two studies [18, 24] investigated diagnostic accuracy. The Cotton test (42.9%), the external rotation test (33.3%), the fibula translation test (61.9%), and the squeeze test (42.9% - 63.3%) all have limitations.

The same systematic review [23] also looked at inter-rater reliability of two studies [24, 25] Good reliability was found for the external rotation test (0.73 and 0.74). Fair reliability was found for the squeeze test (0.46 and 0.49) and ligament palpation (0.49). Poor reliability was found for the Cotton test (0.16) and the fibula translation test (0.28).

In 2015 the Australian research group that wrote the systematic review presented their results of a cross-sectional diagnostic accuracy study in 87 participants (78% male). [16] They found diagnostic accuracy to be 66.7% for the external rotation stress test, 56.3% for local tenderness of the ligaments, and 60.9% for the squeeze test.

## IMAGING

### Radiographs (Figure 9)

Standard x-rays (AP/mortise and lateral) of the ankle are generally used to rule out malleolar fractures. A useful tool in detecting syndesmotic diastasis may be the evaluation of the space between tibia and fibula, measured on the injured and healthy side. With syndesmotic instability, the clear space widens (diastasis) while the overlap is reduced. Generally, a tibiofibular clear space of less than 6 mm in the mortise view is considered normal [26] In a systematic review looking at accuracy of

imaging, the pooled sensitivity for X-ray was 0.53 and the specificity was 0.98 respectively. [27]

### Computertomography (Figure 10)

CT scanning is an accurate method of detecting syndesmotic injuries. CT scanning of both ankles allows determination of fibular shift, rotation, shortening and the exact location of bony avulsions. Care is taken to evaluate the fibular rotation and tibiofibular distance in the horizontal plane at exactly the same level as on the uninjured side. Coronal reconstruction allows exact determination of a lateral shift of the talus and measuring of the fibular length. Generally, side-to-side differences of more than 2 mm are considered pathologic. In a recent study the three most responsive CT measurements for detecting isolated syndesmotic malreduction were described. [28] The clear space for lateral translation (Leporjärvi), the anterior tibiofibular distance for posterior translation as well as the talar dome angle for external rotation of the fibula (Nault). In diagnostic meta-analysis, the pooled sensitivity and specificity were 0.67 and 0.87 for CT respectively.[27]

### MR- Imaging (Figure 11)

MRI has been shown to effectively display the components of the syndesmotic complex with high interobserver agreement.[29] MRI has 93% specificity and 100% sensitivity for injury of the AiTFL, and 100% specificity and sensitivity for injury of the PiTFL compared with arthroscopy in acute injuries.[30] In diagnostic meta-analysis, the pooled sensitivity and specificity were 0.93 and 0.87 for MRI. [27]

### Ultrasound (Figure 12)

Side to side difference of tibiofibular clear space can be evaluated with ultrasound. Differences were less than 1mm in all positions with high ICC values between ankles in one study. [31] The authors conclude that by using 3D-US, they were able to consistently evaluate the clear space with good reliability. One other study

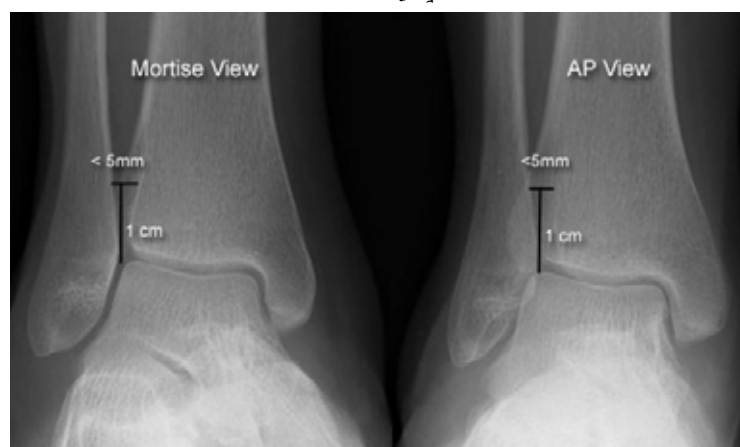reported a sensitivity of 0.89 and specificity of 0.97 for diagnosing syndesmotic insufficiency. [32]

### Arthroscopy (Figure 13)

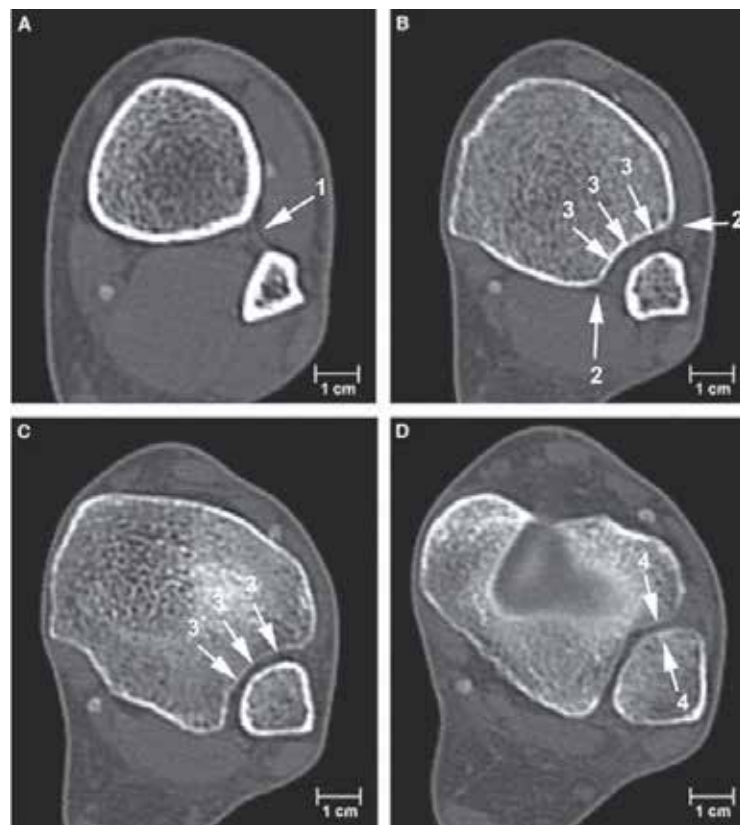
Arthroscopy is the gold standard for diagnosis of ankle syndesmosis injury. [30, 33, 34] However the arthroscopy is a surgical intervention, unlike other imaging modalities, which are non-invasive. Recent developments such as the Nanoscope™ (Arthrex GmbH, Munich, Germany), a needle arthroscopy tool, may become beneficial.

### Bone Scintigraphy (Figure 14)

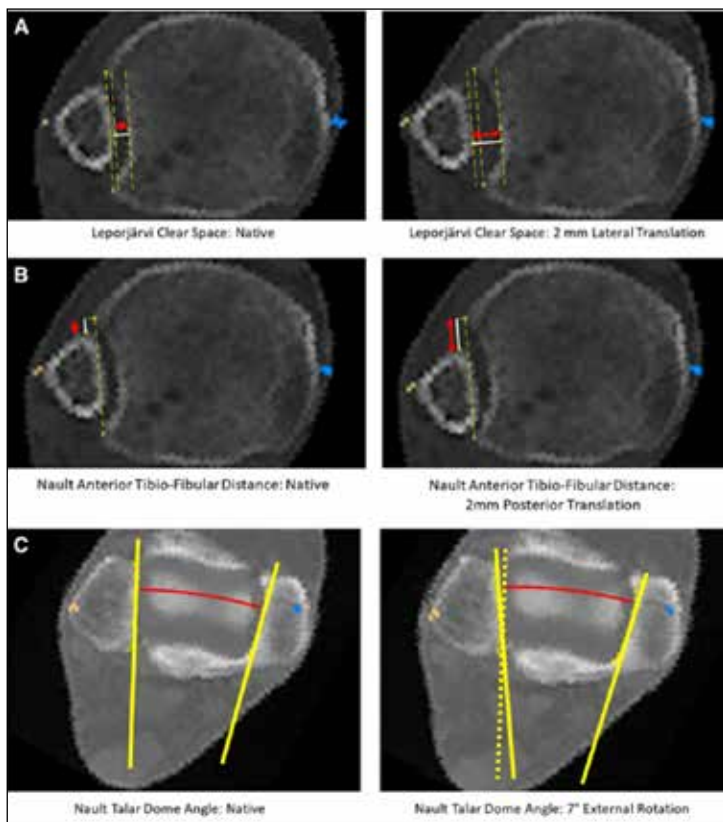
Standard three-phase TC bone scan is a less common used imaging test with low specificity. During the third “bone” phase using high-resolution collimators the anterior, medial, and lateral views of the ankles are used for analysis. In addition, special anterior views with the feet internally rotated by approximately 25° to 35° may be beneficial. One study reported 100% sensitivity, 71% specificity, and 93% accuracy in diagnosing a syndesmotic lesion in the absence of a fracture. [35, 36]



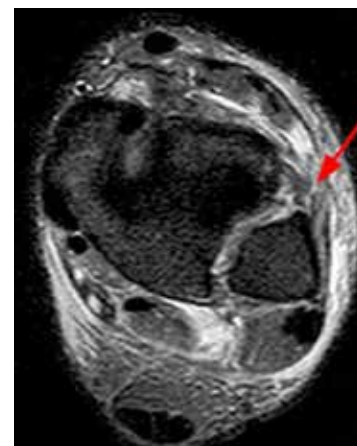
**Figure 9: Ankle X-ray AP and mortise view**  
The specific mortise view is performed in 15 to 20° internal rotation of the foot. In intact syndesmosis the clear space is less than 6 mm.



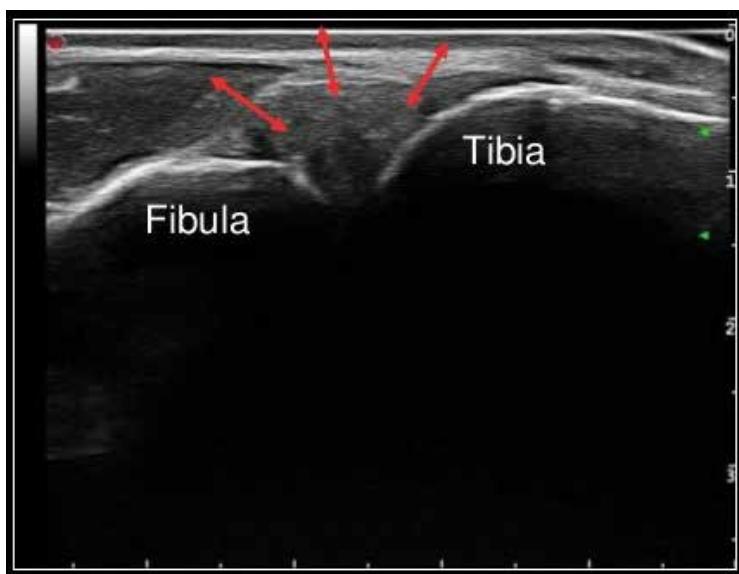
**Figure 10: Ankle axial CT images**  
At the level of the distal tibiofibular joint, from A (cranially) to D (caudally). 1 interosseous membrane; 2 anterior and posterior margins of the tibial incisure; 3 interosseous ligament extends to 1 cm above the tibiotalar joint. 4 flattened aspect of the incisure at the level of the ankle joint.



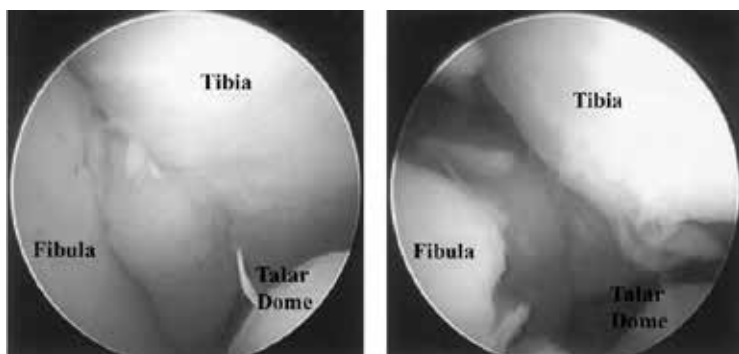**Figure 10B: Ankle axial CT images**  
 From the article of Schon et al. [28] Leporjärvi clear space (a), Nault anterior tibio-fibular distance (b) and Nault talar dome angle (c) methods, performed on a right specimen, showing native measurements on the left frame and malreduced measurements on the right frame. The red arrow/line represents the measured value from each method. The yellow x's represent the anatomic landmarks collected. The yellow axes are construction lines. The blue and orange pixels represent the medial and lateral malleoli, respectively, projected onto the current slice



**Figure 11: MRI imaging**  
 Shows an AiTFL rupture in the T2-weighted axial plane



**Figure 12: Ultrasound examination** of the anterior syndesmosis. The bone contours of the tibia and fibula can be clearly identified. In experienced hands, the soft tissue quality of the AiTFL can be determined. Furthermore, US is the only imaging, which allows a dynamic examination.



**Figure 13: Arthroscopic view of the ankle joint.**  
 Left with an intact syndesmosis. Right shows clearly the diastasis between tibia and fibula, indicating syndesmotomy insufficiency. With tools such as a probe the distance between tibia and fibula can be measured.

## THERAPEUTIC OPTIONS

### *Non-surgical*

The recovery from a syndesmotomy injury takes longer than that for an inversion ankle sprain. Stable grade I sprains are treated with RICE (rest, ice, compress, elevate) for 5-7 days to allow the acute inflammation and swelling to subside. Since clinical testing and radiographic criteria do not have perfect accuracy, patient follow-up is mandatory to ensure improvement in physical signs and symptoms. After the first week, weight bearing is allowed as tolerated in a boot and range of motion exercises are initiated under supervision of a physical therapist. When the patient becomes pain free (on average 2 weeks after trauma) a stabilizing brace is applied, and further functional exercises commence. Grade II injuries can also be managed non-surgically. However when there is a grade II injury seen on MRI but clinical testing reveals instability or an accompanying deltoid lesion, it is necessary to proceed with a fluoroscopic examination (stress-testing) or arthroscopy to assess the syndesmotomy stability.[37] Widening of more than 2mm warrants fixation.

### *Surgical*

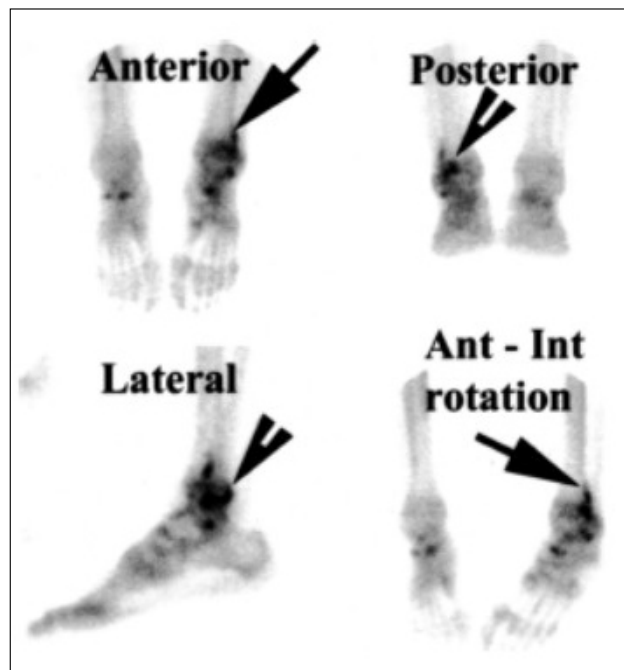
Grade III lesions commonly occur with fractures or in combination with deltoid ligament lesions. However, isolated grade III injuries of the AiTFL also occur and are best managed operatively. Fixation of the fibula in the incisura can be performed with screws, suture buttons or a combination of the two. Some surgeons prefer the use of screws in order to achieve the most stable construct, thereby allowing the torn ligaments to heal in the tightest configuration. Some surgeons prefer the use of suture buttons in order to achieve the most natural physiological envelope of motion within the tibio-fibular joint.

## CONCLUSION AND RECOMMENDATIONS

No single physical examination test is accurate enough to establish the diagnosis of an isolated syndesmotomy injury. A combination of tests could confirm ankle syndesmosis involvement after ankle injuries. An inability to hop, local syndesmosis ligament tenderness, the external rotation and squeeze stress tests may be useful. My personal recommendation is to use the Amendola stabilization test with tape. Although this test

has not been validated, in my opinion it is of additional value. Regarding imaging, in patients with ankle fractures, standard radiographs have good specificity. In cases of isolated syndesmotic injury, X-rays are of limited value. CT and MRI have high sensitivity and specificity irrespective of any accompanying fracture. However the investigations are costly and static. Ideally testing syndesmotic insufficiency requires a dynamic tool. Ultrasound has a great diagnostic potential. The Boston group of DiGiovanni is expected to publish on this topic in the near future. Arthroscopy until now still remains the "gold standard". MRI has similar accuracy to arthroscopic findings but will not be invasive. The diagnostic algorithm for acute syndesmotic injuries therefore consists of proper

history taking (a-priori chance in athletes), a combination of physical examinations with functional tests and MRI. In the near future dynamic CT or ultrasound might become alternatives. ■



*Figure 14: TC Bone Scan  
Increased but more diffuse uptake at the tip of the lateral malleolus in the right foot, at the site of ligamentous injury.*

## References

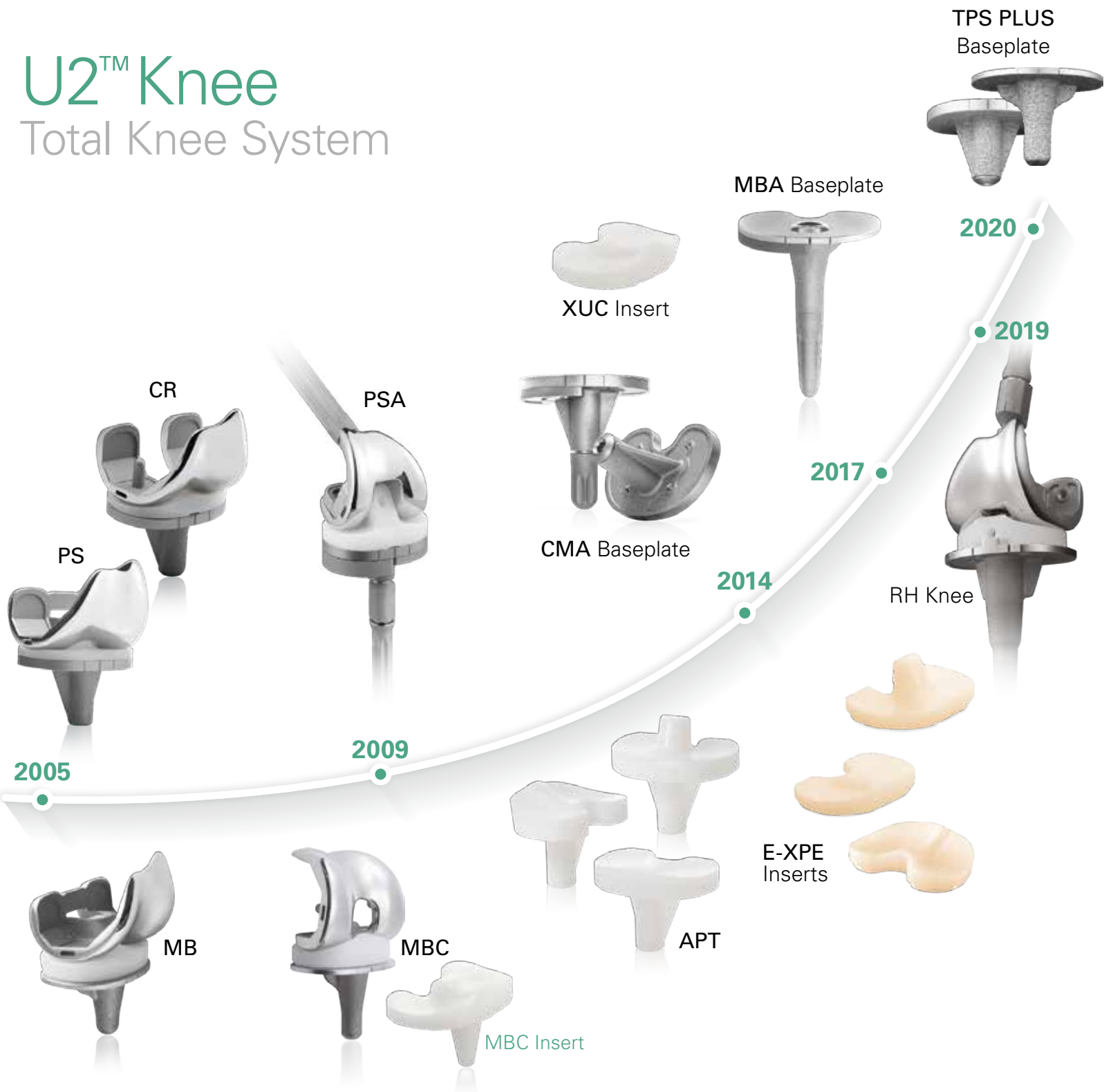
1. HERMANS, J.J., ET AL., ANATOMY OF THE DISTAL TIBIOFIBULAR SYNDESMOSIS IN ADULTS: A PICTORIAL ESSAY WITH A MULTIMODALITY APPROACH. *J ANAT*, 2010. 217(6): P. 633-45.
2. BASSETT, F.H., 3RD, ET AL., TALAR IMPINGEMENT BY THE ANTEROINFERIOR TIBIOFIBULAR LIGAMENT. A CAUSE OF CHRONIC PAIN IN THE ANKLE AFTER INVERSION SPRAIN. *J BONE JOINT SURG AM*, 1990. 72(1): P. 55-9.
3. EBRAHEIM, N.A., ET AL., ANATOMICAL EVALUATION AND CLINICAL IMPORTANCE OF THE TIBIOFIBULAR SYNDESMOSIS LIGAMENTS. *SURG RADIOL ANAT*, 2006. 28(2): P. 142-9.
4. BARTONICEK, J., ANATOMY OF THE TIBIOFIBULAR SYNDESMOSIS AND ITS CLINICAL RELEVANCE. *SURG RADIOL ANAT*, 2003. 25(5-6): P. 379-86.
5. BEUMER, A., ET AL., KINEMATICS OF THE DISTAL TIBIOFIBULAR SYNDESMOSIS: RADIOSTEREOMETRY IN 11 NORMAL ANKLES. *ACTA ORTHOP SCAND*, 2003. 74(3): P. 337-43.
6. BRAGONZONI, L., ET AL., THE DISTAL TIBIOFIBULAR SYNDESMOSIS DURING PASSIVE FOOT FLEXION. RSA-BASED STUDY ON INTACT, LIGAMENT INJURED AND SCREW FIXED CADAVER SPECIMENS. *ARCH ORTHOP TRAUMA SURG*, 2006. 126(5): P. 304-8.
7. RASMUSSEN, O., I. TOVBORG-JENSEN, AND S. BOE, DISTAL TIBIOFIBULAR LIGAMENTS. ANALYSIS OF FUNCTION. *ACTA ORTHOP SCAND*, 1982. 53(4): P. 681-6.
8. HINTERMANN, B., C. SOMMER, AND B.M. NIGG, INFLUENCE OF LIGAMENT TRANSECTION ON TIBIAL AND CALCANEAL ROTATION WITH LOADING AND DORSI-PLANTARFLEXION. *FOOT ANKLE INT*, 1995. 16(9): P. 567-71.
9. RASMUSSEN, O., STABILITY OF THE ANKLE JOINT. ANALYSIS OF THE FUNCTION AND TRAUMATOLOGY OF THE ANKLE LIGAMENTS. *ACTA ORTHOP SCAND SUPPL*, 1985. 211: P. 1-75.
10. RASMUSSEN, O., C. KROMANN-ANDERSEN, AND S. BOE, DELTOID LIGAMENT. FUNCTIONAL ANALYSIS OF THE MEDIAL COLLATERAL LIGAMENOUS APPARATUS OF THE ANKLE JOINT. *ACTA ORTHOP SCAND*, 1983. 54(1): P. 36-44.
11. BODEN, S.D., ET AL., MECHANICAL CONSIDERATIONS FOR THE SYNDESMOSIS SCREW. A CADAVER STUDY. *J BONE JOINT SURG AM*, 1989. 71(10): P. 1548-55.
12. FRITSCHY, D., AN UNUSUAL ANKLE INJURY IN TOP SKIERS. *AM J SPORTS MED*, 1989. 17(2): P. 282-5; DISCUSSION 285-6.
13. LAUGE-HANSEN, N., LIGAMENOUS ANKLE FRACTURES; DIAGNOSIS AND TREATMENT. *ACTA CHIR SCAND*, 1949. 97(6): P. 544-50.
14. ESPINOSA, N., J.P. SMEREK, AND M.S. MYERSON, ACUTE AND CHRONIC SYNDESMOSIS INJURIES: PATHOMECHANISMS, DIAGNOSIS AND MANAGEMENT. *FOOT ANKLE CLIN*, 2006. 11(3): P. 639-57.
15. PENA, F.A. AND J.C. COETZEE, ANKLE SYNDESMOSIS INJURIES. *FOOT ANKLE CLIN*, 2006. 11(1): P. 35-50, VIII.
16. SMAN, A.D., ET AL., DIAGNOSTIC ACCURACY OF CLINICAL TESTS FOR ANKLE SYNDESMOSIS INJURY. *BR J SPORTS MED*, 2015. 49(5): P. 323-9.
17. BOXTIM, M.J., D.A. FISCHER, AND L. NEUMANN, SYNDESMOTIC ANKLE SPRAINS. *AM J SPORTS MED*, 1991. 19(3): P. 294-8.
18. NUSSBAUM, E.D., ET AL., PROSPECTIVE EVALUATION OF SYNDESMOTIC ANKLE SPRAINS WITHOUT DIASTASIS. *AM J SPORTS MED*, 2001. 29(1): P. 31-5.
19. FRICK, H., [DIAGNOSIS, THERAPY AND RESULTS OF ACUTE INSTABILITY OF THE SYNDESMOSIS OF THE UPPER ANKLE JOINT (ISOLATED ANTERIOR RUPTURE OF THE SYNDESMOSIS)]. *ORTHOPAED*, 1986. 15(6): P. 423-6.
20. HOPKINSON, W.J., ET AL., SYNDESMOSIS SPRAINS OF THE ANKLE. *FOOT ANKLE*, 1990. 10(6): P. 325-30.
21. WILLIAMS, G.N., M.H. JONES, AND A. AMENDOLA, SYNDESMOTIC ANKLE SPRAINS IN ATHLETES. *AM J SPORTS MED*, 2007. 35(7): P. 1197-207.
22. BEUMER, A., ET AL., A BIOMECHANICAL EVALUATION OF CLINICAL STRESS TESTS FOR SYNDESMOTIC ANKLE INSTABILITY. *FOOT ANKLE INT*, 2003. 24(4): P. 358-63.
23. SMAN, A.D., C.E. HILLER, AND K.M. REFSHAUGE, DIAGNOSTIC ACCURACY OF CLINICAL TESTS FOR DIAGNOSIS OF ANKLE SYNDESMOSIS INJURY: A SYSTEMATIC REVIEW. *BR J SPORTS MED*, 2013. 47(10): P. 620-8.
24. BEUMER, A., B.A. SWIERSTRA, AND P.G. MULDER, CLINICAL DIAGNOSIS OF SYNDESMOTIC ANKLE INSTABILITY: EVALUATION OF STRESS TESTS BEHIND THE CURTAINS. *ACTA ORTHOP SCAND*, 2002. 73(6): P. 667-9.
25. ALONSO, A., L. KHOURY, AND R. ADAMS, CLINICAL TESTS FOR ANKLE SYNDESMOSIS INJURY: RELIABILITY AND PREDICTION OF RETURN TO FUNCTION. *J ORTHOP SPORTS PHYS THER*, 1998. 27(4): P. 276-84.
26. RAMMELT, S., H. ZWIPP, AND R. GRASS, INJURIES TO THE DISTAL TIBIOFIBULAR SYNDESMOSIS: AN EVIDENCE-BASED APPROACH TO ACUTE AND CHRONIC LESIONS. *FOOT ANKLE CLIN*, 2008. 13(4): P. 611-33, VII-VIII.
27. CHUN, D.I., ET AL., DIAGNOSTIC ACCURACY OF RADIOLOGIC METHODS FOR ANKLE SYNDESMOSIS INJURY: A SYSTEMATIC REVIEW AND META-ANALYSIS. *J CLIN MED*, 2019. 8(7).
28. SCHON, J.M., ET AL., DEFINING THE THREE MOST RESPONSIVE AND SPECIFIC CT MEASUREMENTS OF ANKLE SYNDESMOTIC MALREDUCTION. *KNEE SURG SPORTS TRAUMATOL ARTHROSC*, 2019. 27(9): P. 2863-2876.
29. MUHLE, C., ET AL., TIBIOFIBULAR SYNDESMOSIS: HIGH-RESOLUTION MRI USING A LOCAL GRADIENT COIL. *J COMPUT ASSIST TOMOGR*, 1998. 22(6): P. 938-44.
30. TAKAO, M., ET AL., DIAGNOSIS OF A TEAR OF THE TIBIOFIBULAR SYNDESMOSIS. THE ROLE OF ARTHROSCOPY OF THE ANKLE. *J BONE JOINT SURG BR*, 2003. 85(3): P. 324-9.
31. CHA, S.W., ET AL., RELIABLE MEASUREMENTS OF PHYSIOLOGIC ANKLE SYNDESMOSIS WIDENING USING DYNAMIC 3D ULTRASONOGRAPHY: A PRELIMINARY STUDY. *ULTRASONOGRAPHY*, 2019. 38(3): P. 236-245.
32. CHRISTODOULOU, G., ET AL., THE USE OF SONOGRAPHY FOR EVALUATION OF THE INTEGRITY AND HEALING PROCESS OF THE TIBIOFIBULAR INTEROSSEOUS MEMBRANE IN ANKLE FRACTURES. *J ORTHOP TRAUMA*, 1995. 9(2): P. 98-106.
33. OGLIVIE-HARRIS, D.J. AND S.C. REED, DISRUPTION OF THE ANKLE SYNDESMOSIS: DIAGNOSIS AND TREATMENT BY ARTHROSCOPIC SURGERY. *ARTHROSCOPY*, 1994. 10(5): P. 561-8.
34. TAKAO, M., ET AL., ARTHROSCOPIC DIAGNOSIS OF TIBIOFIBULAR SYNDESMOSIS DISRUPTION. *ARTHROSCOPY*, 2001. 17(8): P. 836-43.
35. FRATER, C., ET AL., SCINTIGRAPHY OF INJURIES TO THE DISTAL TIBIOFIBULAR SYNDESMOSIS. *CLIN NUCL MED*, 2002. 27(9): P. 625-7.
36. MARYMONT, J.V., M.A. LYNCH, AND C.E. HENNING, ACUTE LIGAMENOUS DIASTASIS OF THE ANKLE WITHOUT FRACTURE. EVALUATION BY RADIONUCLIDE IMAGING. *AM J SPORTS MED*, 1986. 14(5): P. 407-9.
37. HUNT, K.J., ET AL., HIGH ANKLE SPRAINS AND SYNDESMOTIC INJURIES IN ATHLETES. *J AM ACAD ORTHOP SURG*, 2015. 23(11): P. 661-73.



UNITED  
ORTHOPEDIC®

# U2™ Knee

Total Knee System



UNITED  
ORTHOPEDIC®

Since 1993, United Orthopedic has had the privilege of supplying world class orthopedic joint replacements, till now, had helped in 38 countries over 250 thousand suffering patients gain back their mobility and quality of life.

**United Orthopedic Corporation EU**

Avenue Général Guisan 60A, 1009 Pully- Switzerland

Phone +41 21 634 70 70 • [contact@uoc-swiss.ch](mailto:contact@uoc-swiss.ch)

[eu.unitedorthopedic.com](http://eu.unitedorthopedic.com)